



Case Report

A Large Anterior Urethral Calculus Presenting as Urethrocutaneous Fistula

Biswanu Sundar Biswal^{1*}, Vikalap Gupta¹, Suren Kumar Das¹, Debabrata Kumar Sabat¹

¹ Department of Urology, IMS & SUM Hospital, Siksha 'O' Anusandhan (Deemed to be University), Bhubaneswar, Odisha-751003, India

* Corresponding author's email: biswanubiswal07@gmail.com

ABSTRACT

Presentation of urinary calculus ranges from painful urination to acute retention. Diagnosed by x-ray pelvis and non-contrast CT, while the removal of stone conducted by various methods. The variety in symptoms sometimes makes clinical diagnosis difficult until radiological investigations confirm it. In this case report we present a case of urethral calculus that is presented as urethrocutaneous fistula. The case was initially diagnosed as urethral stricture; further evaluation revealed urethral diverticulum with large urethral stone in situ proximal to the stricture. The stone extracted surgically, and strictured segment was excised with end-to-end anastomosis was done. Good stream of urine was achieved on further follow up. We concluded that the urethrocutaneous fistula could be one of the presenting features of urethral stone, consideration of possibility of formation of diverticulum and stone formation should be considered in cases of urethral stricture.

Article history:

Received 19 July 2023

Accepted 9 October 2023

Available online 30 December 2023

<https://doi.org/10.47723/kcmj.v19i3.1127>

Keywords: Anterior urethral calculus, Urethral Diverticulum, Urethro-cutaneous fistula



This article is an open access article distributed under the terms and conditions of the Creative Commons Attribution (CC BY) license

<http://creativecommons.org/licenses/by/4.0/>

Introduction

Urethral calculus (UC) presents as dysuria, hematuria, voiding symptoms and acute urinary retention. Diagnosis of impacted urethral calculus may be obvious, but due to different types of clinical symptoms in a case of urethral calculus, dilemma is created. In most cases urethral calculus is secondary to bladder or upper urinary tract however it may be primary due to urethral obstruction in case of urethral diverticulum, stricture or other pathologies. Here we report our finding of a young male who was initially diagnosed with a urethrocutaneous fistula from a urethral stricture, but upon further evaluation he was discovered to have a urethral stone inside a urethral diverticulum.

Case Presentation

A twenty five-year old male patient presented with voiding symptoms and leakage of urine from the perineal region for the past 3 years. Patient has a history of road traffic accident 15 years ago followed by long term urethral catheterisation. He did not seek any medical treatment or surgical intervention during that period. No history of hematuria and acute urinary retention. On physical examination, a firm, well defined palpable swelling was felt at the proximal penile urethra (Figure 1) and an external opening at penoscrotal junction with urinary leakage was also noticed.

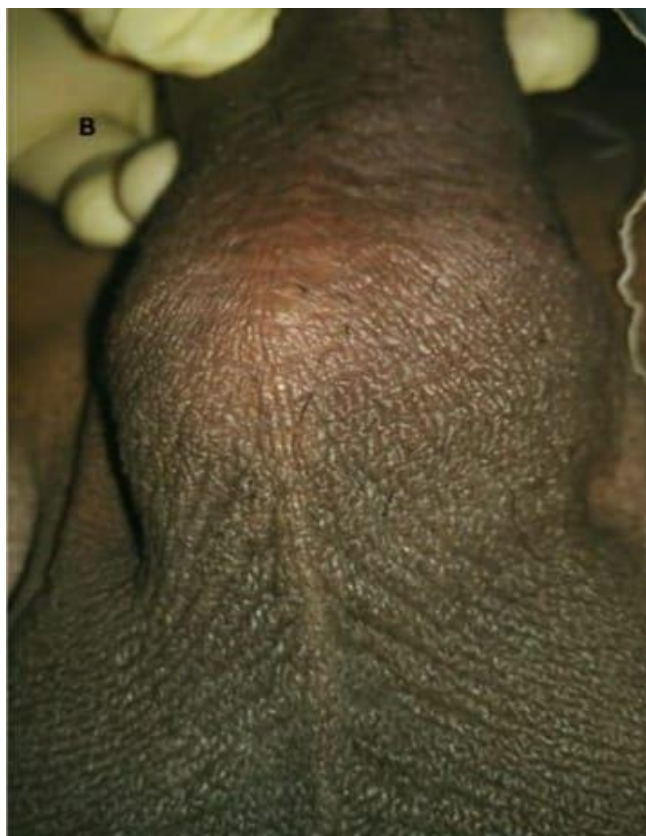


Figure 1. A well-defined palpable swelling at the proximal penile urethra.

Investigations

All Blood biochemistry was within normal limits. Plain radiographic examination of pelvic and penile region confirmed the diagnosis of a giant peno-bulbar urethral calculus. Retrograde urethrography a urethral stone at the peno-bulbar urethra with urethrocutaneous fistula communicating to scrotum and accompanying distal stricture. Ultrasonography of abdomen showed bilateral mild hydronephrosis. Urine Microscopic examination had many pus cells and culture showed *Escherichia coli* as the organism. Serum calcium was within normal range. Urethroscopy Showed a diverticulum near the site of a urethral stricture (Figure 2).

Treatment

The patient was taken for open surgery under Spinal Anaesthesia after proper counseling and consent. Ceftriaxone 1 gram injection was given as prophylactic antibiotic. Patient positioned in lithotomy position. Intraoperatively, a giant calculus measuring 30x25 mm was found in the urethral diverticulum arising just proximal to the short segment urethral stricture (Figure 3). The intact stone was extracted after performing urethrotomy at swelling site directly (Figure 3A and 3B). Then perineal incision was done. Layers opened are skin, fascia, fat up to Bulbospongiosus muscle. Then Bulbospongiosus separated in midline and Corpus spongiosum, and urethra reached. Penis delivered into the incision site. Strictured segment and diverticulum identified, urethra cut proximal and distal to strictured segment and

end to end anastomosis performed using vicryl 4-0 round body absorbable suture over 16 Fr Foleys catheter and wound closed in layers. Suprapubic catheter was also placed. The post-operative course was uneventful. Patient was discharged with the Foley catheter on the 4th post-operative day.

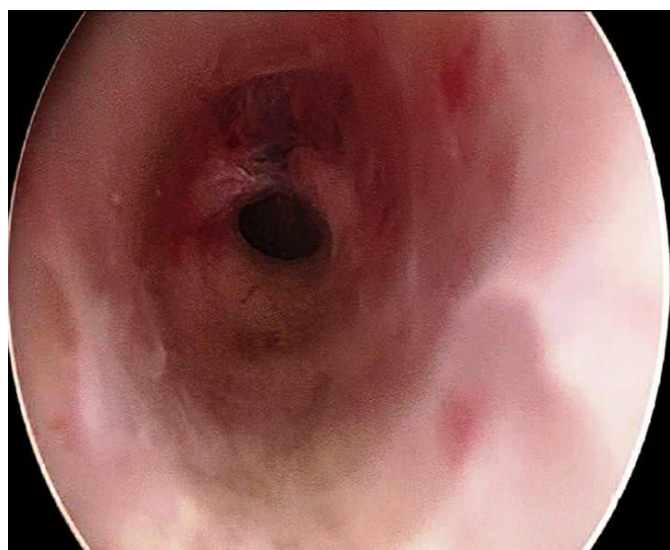


Figure 2. Urethroscopy showing diverticulum.

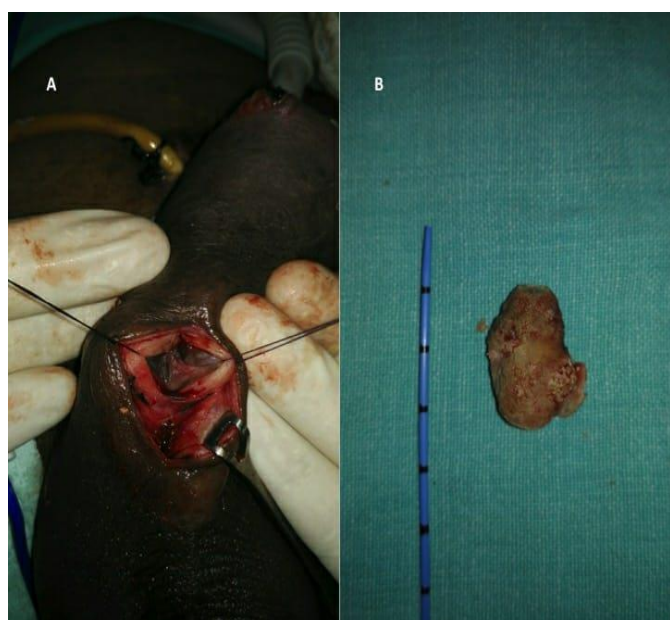

Figure 3. Intraoperatively, a large calculus measuring 30x25 mm was found in the urethral diverticulum arising just proximal to the short segment urethral stricture.

Outcome and Follow-up

Catheter removed after 3 weeks and post catheter removal a uroflowmetry was done which showed Q max as 25 ml/sec. Suprapubic catheter was removed 2 days after Per urethra catheter

removal, after ensuring that patient was voiding at good flow per urethra Patient was asymptomatic even at 3 months follow up.

Discussion

Contribution of urethral calculi in urinary tract stones is only 0.3-2%. UC occur more in males and occurs at higher incidence in children of developing countries, due to malnutrition, bladder stones formed. Stones then migrate to urethra (1). Urethral stones are divided into primary and secondary stones. Secondary stones are those which are formed in kidney, ureter and bladder and then migrate to urethra. On the other hand, primary stones form in urethra itself, formed secondary to an obstruction due to stricture or inside a diverticulum. The incidence of urethral stone is more in posterior urethra than in anterior urethra (2).

Urethral stones present with variety of clinical symptoms ranging from dysuria, rectal pain, blood in urine, supra-pubic pain, and acute urinary retention. Calculus may be palpable in some cases. However, sometimes it may not be evidently palpable due to the surrounding inflammation and if the stone is small. As a result of a variety of clinical symptoms, proper diagnosis can be delayed, as seen in this case. In our case, the initial diagnosis of urethrocutaneous fistula was made based on history and clinical examination. Differential diagnosis of urethral calculus may include urethral tumor or foreign bodies (3).

Most urethral stones are seen on a plain X-ray pelvis due to their radio-opaque nature. Some of the urethral stones are not diagnosed on plain X-ray film as they are radiolucent. In many cases, cystourethroscopy is used in diagnosis of urethral stones (4). Penile ultrasound can also be used to diagnose urethral stone. However, computed tomography scan may be required rarely in diagnosing of urethral stones (1).

There is variety of modalities for treating urethral stones. The modalities include non-invasive, minimally invasive (endoscopic) and open surgical removal. Choice of modality for a particular case depends on location and size of stones and accompanying pathology. Small stones can expel spontaneously. Using a 2% lidocaine jelly instillation, may help in spontaneous expulsion. Posterior urethral stones may need push back into bladder cystoscopically and then its removal endoscopically. Urethral stones may be fragmented by holmium laser (5). Urethral diverticular urethral stones can be removed by breaking them by ultrasonic lithotripter (6). Urethral stones can be removed by forceps, but it may cause urethral mucosal injury. Open surgery is final resort for bigger calculus and in case of failed minimal-invasive techniques.

Since the patient was lost from follow up after 3 months, the delayed results of the urethroplasty was not reported.

Conclusion

We concluded from this case that urethral stricture can lead to bladder diverticulum and stones can form in that urethral diverticulum. It can cause symptoms of bladder outlet obstruction and proximal hydronephrosis, which if unnoticed can lead to renal insufficiency. Urethral stone can be associated with urethral stricture, urethrocutaneous fistula or urethral diverticulum (7,8). Diagnosis of urethral stones can be made on a plain X-Ray of pelvis as they are

mostly radio opaque. Urethral stone diagnosis may be missed sometimes due to its variety of clinical presentations. Sometimes urethral stones may be found incidentally when investigating for other differential diagnosis. Most urethral stones can be removed endoscopically, or they may spontaneously expel. However, we may need open surgery for large stones or any associated diseases.

Acknowledgments

The authors are highly grateful to the Dean IMS & SUM Hospital for providing all the support and encouragement during the study. The authors are also thankful to the patients and his family for providing the consent to publish this study.

Funding

No source of financial support was provided for this study.

Conflict of Interest

Authors declare no conflict of interest.

Ethical Approval

A written consent was approved by the patient to publish this study.

ORCID

| | |
|----------------------|---------------------|
| Biswanu Sundar Biswa | 0009-0008-5421-8319 |
| Vikalap Gupta | 0000-0001-8074-8542 |
| Suren Kumar Das | 0000-0003-2676-0051 |
| Debabrata Sabat | 0009-0009-0145-0007 |

References

- [1] Kamal B, Anikwe R, Darawani H, Hashish M, Taha S. Urethral calculi: presentation and management. *BJU international*. 2004;93(4):549-52.
<https://doi.org/10.1111/j.1464-410X.2003.04660.x>
- [2] Kaplan M, Atakan IH, Kaya E, Aktoz T, Inci O. Giant prostatic urethral calculus associated with urethrocutaneous fistula. *International journal of urology*. 2006;13(5):643-4.
<https://doi.org/10.1111/j.1442-2042.2006.01374.x>
- [3] Turo R, Smolski M, Kujawa M, Brown SC, Brough R, Collins GN. Acute urinary retention in women due to urethral calculi: A rare case. *Canadian Urological Association Journal*. 2014;8(1-2):E99.
<https://doi.org/10.5489/cuaj.1573>
- [4] Koga S, Arakaki Y, Matsuoka M, Ohyama C. Urethral calculi. *British journal of urology*. 1990;65(3):288-9.
<https://doi.org/10.1111/j.1464-410X.1990.tb14730.x>
- [5] Maheshwari PN, Shah HN. In-situ holmium laser lithotripsy for impacted urethral calculi. *Journal of endourology*. 2005;19(8):1009-11.
<https://doi.org/10.1089/end.2005.19.1009>
- [6] Zhou T, Chen G, Zhang W, Peng Y, Xiao L, Xu C, et al. Impacted anterior urethral calculus complicated by a stone-containing diverticulum in an elderly man: outcome of

transurethral lithotripsy without resection of the diverticulum. SciELO Brasil; 2013. p. 754-5.

<https://doi.org/10.1590/s1677-5538.ibju.2013.05.20>

- [7] Sun M, Xu W, Guo S, Ma W, Xu H, Sun R. Giant urethral calculus in anterior urethral diverticulum: a case report. BMC urology. 2019;19(1):1-5.

<https://doi.org/10.1186/s12894-019-0498-9>

- [8] Gadimaliyev E. Urethral diverticulum calculi in a male: a case report. Case Reports in Urology. 2013;2013.

<https://doi.org/10.1155/2013/437106>

To cite this article: Biswal BS, Gupta V, Das SK, Sabat DKA. Large Anterior Urethral Calculus Presenting as Urethrocutaneous Fistula. AL-Kindy College Medical Journal. 2023;19(3):36–39.

<https://doi.org/10.47723/kcmj.v19i3.1127>