

Dorsal plication during penile orthoplasty with and without neurovascular bundle mobilization A comparative clinical trial conducted At Ghazy Al-Hariri teaching hospital for surgical specialties (2013 -2015)

*Yousuf Mohammed Alhallaq , **Yahia Muhaisin Ali , ***. Harth Mohamed Kamber Al-Saadawi

ABSTRACT

Background: Dorsal plication on each side of the penis at the 2 and 10-o'clock positions had been a mainstay for correction of ventral penile curvature. However, because only the 12-o'clock position proved to be a nerve-free zone, dorsal plication at the 12-o'clock position can be advocated.

Objectives: To evaluate tunica albuginea plication with and without neurovascular bundle mobilization in patients with ventral penile curvature.

Type of the study: A prospective study.

Methods: A 34 patients with a mean age of (4.8 ± 0.54) years, Who still have ventral penile curvature all $\leq 30^\circ$ after degloving of penis with or without other orthoplasty technique, randomized into two groups, in group (A) 17 patients subjected to midline dorsal penile plication at 12-o'clock, whereas in group (B) 17 patients subjected to plication of tunica albuginea at 2 and 10-o'clock positions after neurovascular bundle mobilization.

Results: 94.1% of group (A) and 88.2% of group (B) Patients have satisfactory appearance of the penis. No complications were reported in both groups

Conclusions: The incision and plication of tunica albuginea with neurovascular bundle mobilization is long and more invasive procedure than Midline dorsal penile plication with no significant differences in outcome.

Keywords: Penile curvature, plication, Neurovascular bundle.

*Al-Kindy College Medical Journal 2016: Vol. 12 No.2
Page: 11-17*

*Consultant Urologist, F. I. C. M.S. Urology, F.E.B.U.(Consultant in Urology and Kidney Transplant)

** M. B. Ch. B., F.I.C.M.S

*** M. B. Ch. B., F.I.C.M.S

Received 16th June 2015, accepted in final 17th April 2016

Corresponding to: Harth Mohamed Kamber Al-Saadawi

Significant Congenital curvature of the penis were estimated to occur in 3-5% of the general population.⁽¹⁾ In association with hypospadias neither congenital anomaly of the urethra nor periurethral tissues are involved in the etiopathology of most cases of penis deviation, but rather imperfect development of the tunica albuginea of the cavernous bodies.⁽²⁾ The anatomy of the neurovascular bundle in the human penis characterized by an extensive neuronal network starting at the 11 and 1 o'clock position along the tunica of the corporal body and the nerves continued to the urethral spongiosum junction and there is no nerves at the 12 o'clock position (nerve-free zone).^(3,4) (Figure 1)

Mobilization of the neurovascular bundle is anatomically possible. Histological analysis of normal and hypospadiac human fetal penises prove that the Perforating nerves into the erectile bodies were not found along the dorsal or lateral aspect of the corporal bodies.^(2,5) At the termination of the corpora cavernosum the nerve pierce into the glans of the penis surrounding the urethra. This relationship may have implications during hypospadias repair when extensive mobilization of the dorsal glandular urethra is proposed.^(6,7) The first description of successful surgical correction was by Nesbit although many modifications have been intended.⁽¹⁾ Nesbit reported dorsal plication sutures to straighten the bending penis after removing elliptical segments of the tunica albuginea from the lateral aspect of each corpus cavernosum.⁽⁸⁾ (Figure 2)

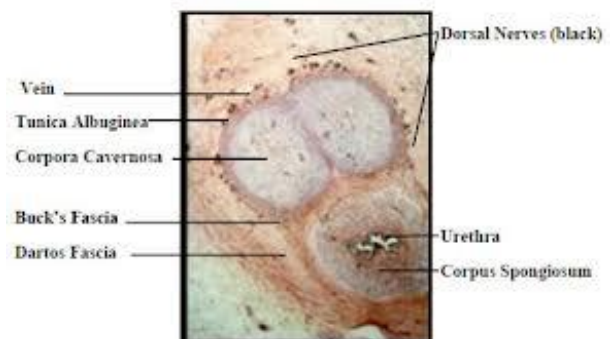


Figure 1: demonstrating corporal bodies of penis with nerves distribution.⁽⁴⁾

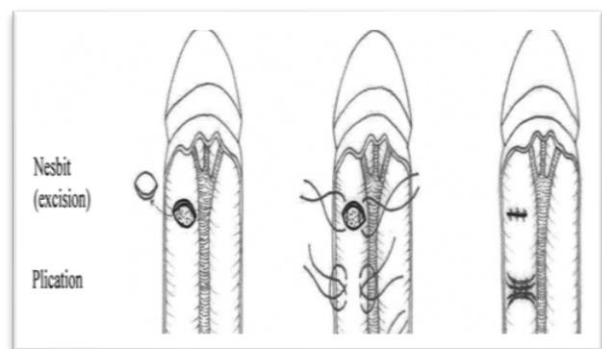


Figure 2: Schematic illustration of different surgical procedures on dorsal part of penis⁽¹²⁾

Several other reconstructive techniques have been proposed for the correction of congenital curvature. Similar to the Nesbit technique, tunica albuginea plication with or without transversal parallel sutures⁽⁹⁾ and longitudinal incision with transverse suturing^(10, 11) may be performed on the convex part of the penis.

In 1994, Baskin and Duckett modified the Nesbit procedure and avoided elliptical excisions in favor of plicating the incised tunica albuginea, fixing the outer edges with permanent sutures, and dunking the intervening tissue.⁽⁵⁾

Initially, Baskin and Duckett recommended that dorsal plication of the tunica albuginea on each side of the penis at the 2- and 10- o'clock positions should be taken at the point of maximal bend and Buck's fascia with the neurovascular bundles elevated on each side. Since then, this plication technique has been prevalent for the correction of penile curvature with or without hypospadias.⁽⁵⁾

In 2000, however, after histological observations showed that only the 12-o'clock position was nerve free, Baskin et al recommended that penile plication be conducted at the 12-o'clock position without incision of the tunica albuginea.⁽¹³⁾

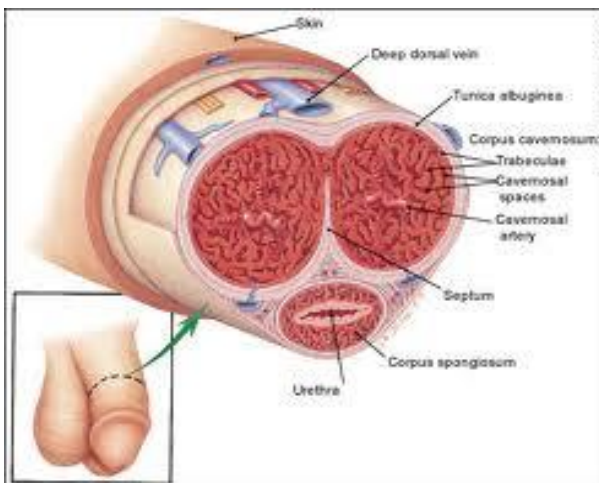


Figure 3: Cross section of the penis, demonstrating corporal bodies, penile fascia, vessels, and nerves.⁽¹⁴⁾

In 2009, Snodgrass and Prieto recommended that ventral curvature may resolve with ventral degloving and dartos dissection, the ventral curvature less than or equal to 30 degrees remaining after ventral dissection can be corrected by midline dorsal plication. Ventral curvature greater than or equal to 30 degrees after ventral dissection can be straightened by either single ventral corporeal incision with grafting or multiple ventral corporeal incisions without grafting. During these maneuvers the urethral plate and adjacent corpus spongiosum often can be maintained intact by elevating them from the corpora. Persistent ventral curvature after these maneuvers requires urethral plate transection.⁽¹⁵⁾

Optimal management of ventral curvature greater than 30 degrees remains uncertain. Multiple plications using 5-0 to 4-0 polypropylene are described, although concerns for both recurrent curvature and loss of penile length increase when more than one plication is performed.⁽¹⁶⁾

This extent of bending after skin degloving and ventral dartos dissection is considered as a disproportion between the ventral and dorsal aspects of the corpora cavernosa.⁽¹⁷⁾

Ventral lengthening traditionally involves transection of the urethral plate followed by transverse incision from the 3- to 9-o'clock position into the tunica albuginea to expose erectile tissues of the corpora in the region of greatest curvature (Figure 4). The resultant defect has been closed using dermal grafts, small intestine submucosa, or tunica vaginalis flaps or grafts. No evidence indicates the outcome is significantly influenced by choice of materials for corporotomy repair. Most proponents of the use of small intestine submucosal have used single-layer material.

Urethral plate transection to facilitate corporeal grafting requires substitution urethroplasty using preputial flaps or grafts in either one or two stages. Alternatively, the urethral plate and adjacent corpus spongiosum can be preserved and dissected from the underlying surface of the corpora cavernosa. Elevation of the plate alone has been reported to correct curvature.⁽¹⁸⁾ Or it can be combined with corporotomy and grafting.⁽¹⁹⁾ Dissection under the urethral plate can also be continued proximally to near the membranous junction, elevating the normal urethra from the corpora. This maneuver was adapted from urethral stricture repair in which mobilization of the urethra combined with its inherent elasticity allows gaps to 5 cm in adults to be bridged.⁽²⁰⁾ After dissection of the urethral plate and urethra, residual ventral curvature can be corrected by dorsal plication or ventral corporotomy. rather than a single corporotomy with grafting, two to three transverse incisions can be made into the tunica albuginea without exposing erectile spongy tissue or need for grafting. Ventral curvature that persists despite mobilization of the urethral plate and urethra requires urethral plate transection for straightening.⁽¹⁵⁾

Patients and Methods: A comparative clinical trial conducted from March 2013 to February 2015 at Ghazy Al-Hariri hospital. A 34 patients with hypospadias and congenital ventral penile curvature were randomized into two groups with different degree of chordee: group (A) consisted of 17 patients in whom midline dorsal plication technique at the 12 o'clock position were performed to repair penile curvature with avoidance of neurovascular bundle mobilization, group (B) consisted of 17 patients in whom dorsal plication technique by incision of tunica albuginea at 2- and 10-o'clock positions of the corporeal bodies with neurovascular bundle mobilization were performed and whole patient involved in our study. Dorsal tunica albuginea plication is chosen if the angle of the penile curvature is equal or

less than 30° after degloving of penis, and to correct the curvature more than 30° other procedure needed with plication such as mobilization of urethral plate, corporotomy or urethral plate transection (Figure 4).

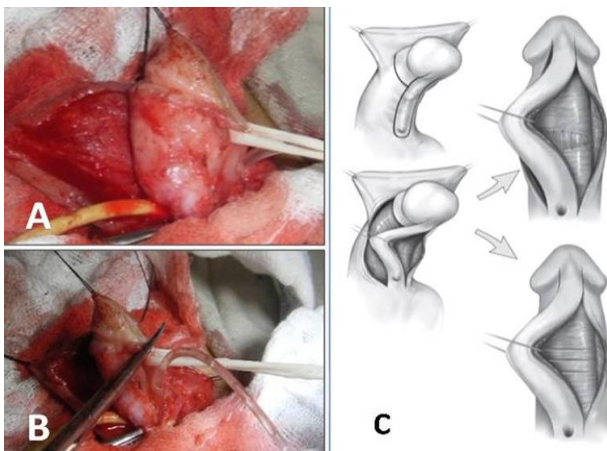


Figure 4: (A) mobilization of urethral plate. (B) urethral plate transection. [(C) ventral corporeal incision with grafting or multiple ventral corporeal incision without grafting⁽²¹⁾].

The mean age of patient was (4.8 years) with a range of (1-13 years), all patient were followed-up for 6-12 months. All patients parents were informed about the study, the surgical procedure and possible complications before signing consents. Patients with a curvature improved by degloving without plication were excluded from the study.

Surgical techniques:

Plication after neurovascular bundle mobilization:

A circumferential subcoronal incision was made and the penis degloved to the penile root. After a constricting rubber band was applied at the penile root, an artificial erection was induced by normal saline injected through a butterfly needle into one corporal body. The direction, degree of angulation and the maximal convexity of the penile curvature were determined.

The overlying Buck's fascia and the neurovascular bundle carefully dissected free from the tunica albuginea, start lateral to the corpus spongiosum and carry the incision medially. (about 1 cm long and 1 cm wide) and elevated with vascular tapes to facilitate the application of the exposed tunica albuginea (Figure 5). When the penis detumesced, Allis clamps were used to grasp the underlying tunica albuginea at point of maximal curvature, A second artificial erection was induced to check the result of the correction. Parallel incisions 6 to 8 mm apart and 3 to 4 mm long arc made through the tunica albuginea transversally at 2-o'clock and 10- o'clock position (Figure 6). The outer edges of the incisions arc approximated with 2/0 synthetic absorbable polyglactin (Vicryl) in a way that buries the knot (Figure 6). The straight penis is verified by again inducing an intraoperative artificial erection, and the divided Buck's fascia is closed. The penile skin was

retracted, closed with 4/0 synthetic absorbable polyglactin (Vicryl) and wrapped in a light compressive dressing with a self-adhesive bandage. A urethral catheter was left in place for 24 h.

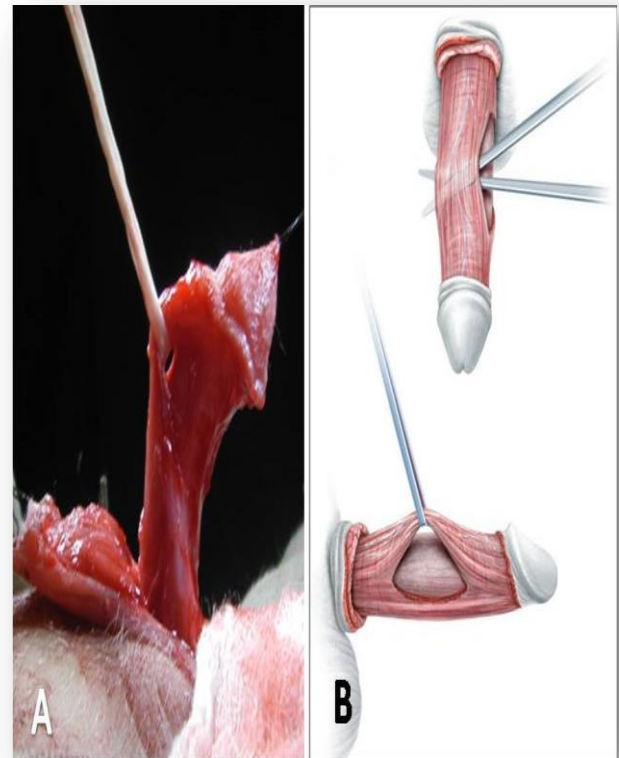


Figure 5: Neurovascular bundle mobilization and elevated with vascular tapes. (A) In medical city \Iraq, (B).⁽²²⁾

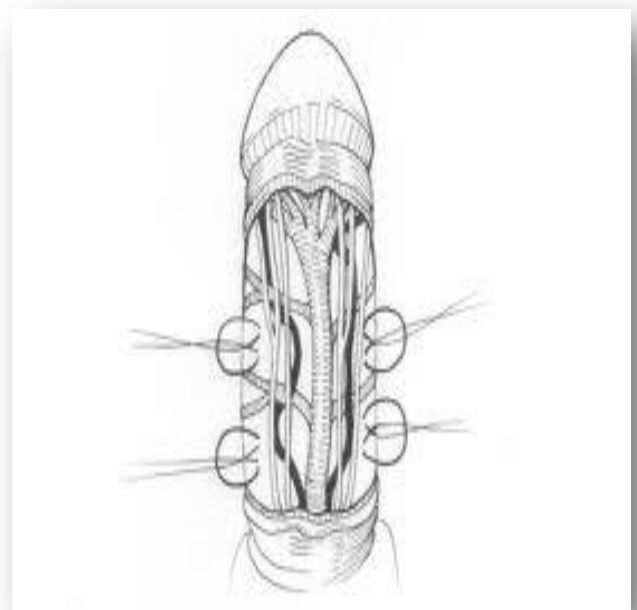


Figure 6: Dorsal penile plication at 2 and 10- o'clock position after neurovascular bundle mobilization.⁽²³⁾

Midline dorsal plication :The plication technique performed on the patients in our study by start with circumcising incision is performed, skin degloving to the penile root, Buck's fascia is cut longitudinally of the point of maximal curvature at the 12-o'clock position and tunica albuginea is exposed for plication (Figure 7.B). induction of an artificial erection test and placement of 1 or 2 polypropylene 4/0 or 5/0 plication sutures at the midline dorsal aspect of the point of maximal curvature (Figure 7.C).The straight penis is verified by inducing an intraoperative artificial erection. The penile skin was retracted, closed with 4/0 synthetic absorbable polyglactin (Vicryl) and wrapped in a light compressive dressing with a self-adhesive bandage. A urethral catheter was left in place for 24 h.

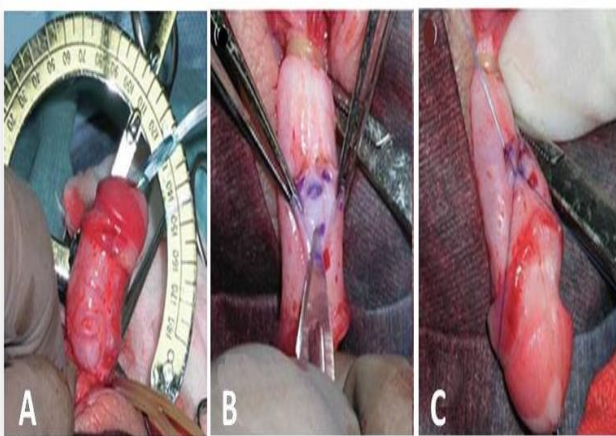


Figure 7: Dorsal plication (A) Artificial erection demonstrates 30-degree curvature. (B) Buck's fascia is cut longitudinally at the 12 o'clock position (C) Permanent sutures (5) polypropylene are used for plication and outer edges approximated in a way that buries the knots. (24)

Statistical analysis: SPSS (statistical package for social sciences) software for windows version 18 , was used for entering and analysis of patient's data.

Descriptive statistics for continuous variables (age, time) were presented as mean \pm standard error of mean, and as frequencies and proportions (percentages) for categorical variables.

Different tables were performed and appropriate statistical tests were used , Chi square (χ^2) test was used for comparison of categorical variables and Students' t test was used for comparison of continuous variables . In all statistical tests and procedures , level of significance (P. value) was two tailed and set at less than or equal to 0.05 to be considered as significant difference. Finally all data and information were presented as tables and \ or graphs.

Results: There were 34 patients in this study divided into two groups; Group A (17) patients subjected to MP and group B (17) subjected to neurovascular bundle mobilization.

The mean age of patients in group A was (4.95 \pm 0.78) years and for group (B) was (4.7 \pm 0.78) years. No

significant difference had been found in the age in between both groups regarding the mean age and age groups, $P > 0.05$, table 1.

Table 1. Pre-operative characteristics of patients age group distribution

Characteristic s	Group				P.value	
	A (N=17)		B (N=17)			
	N	%	N	%		
Number of patients	17	50%	17	50%	1 ns	
Age	01-Mar	7	41.20 %	7	41.20 %	> 0.05 ns
	04-Jun	6	35.30 %	7	41.20 %	
	07-Sep	3	17.60 %	2	11.80 %	
	> 9	1	5.90%	1	5.90%	
	Mean \pm SE*	4.95 \pm 0.78		4.7 \pm 0.78		4.8 \pm 0.54

* SE; standard error of mean.
ns ; not significant

The results and clinical characteristics of patients were summarized in table 2 and figure 8.

Ventral Curvature degree after degloving : there were 11 patients with ventral curvature $\leq 30^\circ$ in group (A) versus 12 patients in group (B), the remaining patients were with ventral curvature $> 30^\circ$, no significant difference had been found in between both groups, $P > 0.05$.

- Overall Satisfaction:** As concerns the patients , 16 patients (94.1%) in group (A) declared themselves completely satisfied, versus one patient (5.9%) partially satisfied., where as for group (B) 15 patients (88.2%) declared themselves completely satisfied, and two patients (11.8%) partially satisfied, nobody was unsatisfied in both groups. No significant difference ($P > 0.05$) in between both groups had been found.
- Recurrence of curvature:** One patient (5.9%) in each group presented with a minimum relapse that needed surgical revision after 3-6 months. The remaining 16 patients (94.1%) in each group, obtained and maintained a perfect correction after surgery.
- Hypercorrection:** Non of the 34 patients with contralateral deviation were observed in the postoperative period .
- Shortening of penis:** 2 patients (11.8%) in group (A) and 3 patients (17.6%) in group (B) reported a slight shortening of the penis following surgery, with no statistical significance .
- Perception of the suture/plication:** Non of the patients in group (A) and only one patient (5.9%) in

group(B) reported perception of the stitches and the plication to touch.

6. **Time of operation** : The mean time of procedure was (13.2 ± 0.4) minutes in group (A) compared to (26.9± 0.6) in group (B), it had been significantly found (P=0.0007), that MP procedure needed shorter time than neurovascular bundle mobilization procedure.

Table 2: The results and clinical characteristics of patients

Clinical characteristics		Group A (N=17)		Group B (N=17)		P.value
		N	%	N	%	
Ventral Curvature degree after degloving	≤ 30°	11	64.70%	12	70.60%	>0.05 ns
	>30°	6	35.30%	5	29.40%	
Overall Satisfaction	Complete	16	94.10%	16	94.10%	>0.05 ns
	Partial	1	5.90%	1	5.90%	
Perception	No	17	100%	16	94.10%	>0.05 ns
	Yes	0	0.00%	1	5.90%	
Recurrence	Minimum	1	5.90%	2	11.80%	>0.05 ns
	Optimal	16	94.10%	15	88.20%	
Hypercorrection (dorsal curvature)	No	17	100%	17	100.00%	>0.05 ns
	Yes	0	0.00%	0	0.00%	
Shortening	No	15	88.20%	14	82.40%	>0.05 ns
	Slight	2	11.80%	3	17.60%	
Time of procedure (minute)	Mean ± SE*	13.2 ± 0.4		26.9 ± 0.6		0.0007 sig
	Range	10 - 15		22 - 30		

SE; standard error of mean
ns ; not significant
sig; significant

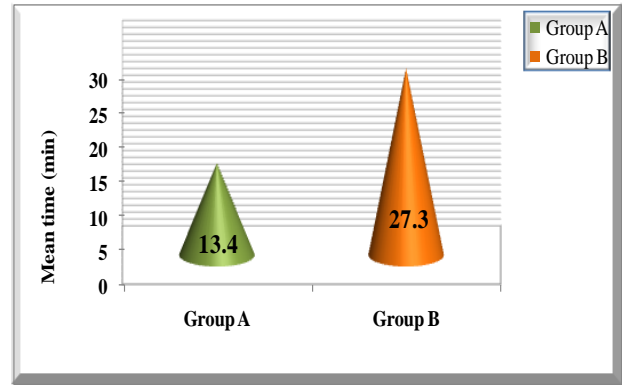
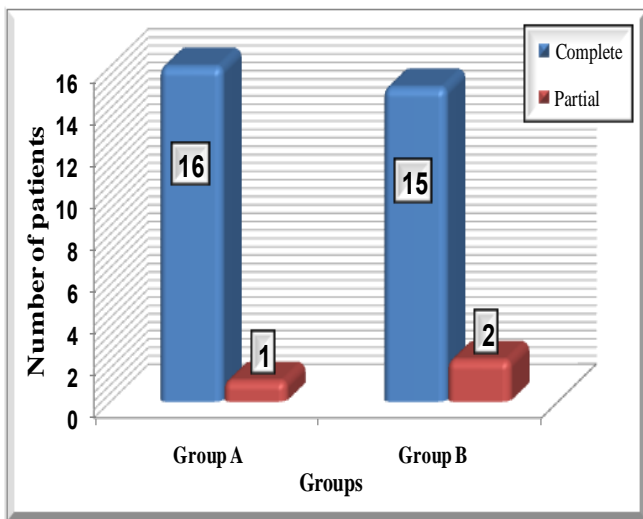


Figure 9: Mean time of operation compared in between study groups

Discussion: Some cases of penile curvature are caused by skin tethering and they can be successfully managed by circumferential dissection along Buck’s fascia to the level of the penoscrotal junction. When possible, the release of spongiosal tissue causing chordee achieves additional straightening. However, in the remaining cases a satisfactory result is not achieved and an additional procedure is required.⁽²⁵⁾

Most current penile curvature repair techniques involve dissection or excision of the tunica albuginea, requiring neurovascular bundle mobilization. Several studies of neurovascular bundle anatomy have demonstrated the distribution of nerve fibers, which run from the 11 and 1 o’clock positions around the corporeal bodies to the 7 and 5 o’clock positions, leaving the 12 o’clock position as the only nerve-free position.^(4,5)

These findings led to changing the previous recommendation for curvature repair with the tunica albuginea plication technique. The proposed technique, namely the midline dorsal plication technique, involves no neurovascular bundle mobilization dissection or tunica albuginea excision.

In these studies the dorsal midline position was identified as the thickest and strongest position of the tunica albuginea, facilitating repair with the proposed method. Further study used human fetal penile specimens to examine the feasibility of neurovascular bundle mobilization and led to the conclusion that safe mobilization is theoretically possible, and no evidence of perforating branches from the dorsolateral nerve complex into the corporeal bodies was identified. practically mobilization is often difficult due to the small distance between nerve fibers and the tunica albuginea. Therefore, Baskin et al have continued to advocate the midline dorsal plication technique.⁽¹³⁾

Since data on the long-term results of penile curvature repair in pediatric patients are lacking, the clinical significance of neurovascular bundle dissection or tunica albuginea mobilization is unclear, and the neuronal damage has not yet been evaluated. Concerns have been raised regarding possible ligation of the dorsal vein. Visualization of the dorsal vein in the pediatric population may be difficult. We currently make no effort to identify the vein. This approach is based on

the results of dorsal vein excision in adults with Peyronie's disease who have no adverse effects. ^(13, 26)

The midline dorsal penile plication technique is simple to perform, requires minimal operative time and achieves excellent results in patients with mild to moderate curvature. As long as the clinical significance of neurovascular bundle dissection is unclear, a procedure that avoids it seems preferable. ⁽²⁷⁾

According to our study both procedure give same result but midline dorsal penile plication technique is simple to perform, requires minimal operative time and achieves excellent results for patients with curvature $\leq 30^\circ$ and those with curvature $>30^\circ$ need further technique .

Conclusions: The midline dorsal penile plication technique is a safe, anatomically sound method. It requires minimal operative time and achieves excellent results in patients with penile curvature $\leq 30^\circ$ in those with hypospadias. The technique may also be successfully used for residual curvature after previous repair.

Recommendation: According to our study midline dorsal penile plication technique for patients with hypospadias associated with ventral penile curvature $\leq 30^\circ$, still those with ventral penile curvature $>30^\circ$ need further technique

References:

1. Ebbehøj J, Metz P Congenital penile angulation. *Br. J. Urol.* 1987; 60:264-266.
2. Baskin LS, Duckett JW, Lue TF Penile curvature, review. *Urology*, 1996;48:347-356.
3. Baskin, L., Erol, A., Li, Y. W. et al: Anatomical studies of hypospadias. *J Urol* ,1998; 160: 1108.
4. Baskin, L. S., Lee, Y. T. and Cunha, G. R.: Neuroanatomical ontogeny of the human fetal penis. *Br J Urol* ,1997;79: 628.
5. Baskin LS, and Duckett JW: Dorsal tunica albuginea plication for hypospadias curvature. *J Urol*, 1994; 151: 1668-1671.
6. Barthold, J. S., Teer, T. L. and Redman, J. F.: Modified Barcat balanic groove technique for hypospadias repair: experience with 295 cases. *J Urol*, 1996; 155: 1735.
7. Koff, S. A., Brinkman, J., Ulrich, J. et al: Extensive mobilization of the urethral plate and urethra for repair of hypospadias: the modified Barcat technique. *J Urol*, 1994; 151: 466.
8. Nesbit RM: Congenital curvature of the phallus: report of three cases with description of corrective operation. *J Urol* ,1965;93: 230-232.
9. Chien GW and Aboseif SR: Corporeal plication for the treatment of congenital penile curvature. *J Urol*, 2003; 169: 599 .
10. Hayashi Y, Kojima Y, Mizuno K, Tozawa K, Sasaki S and Kohri K: Modified technique of dorsal plication for penile curvature with or without hypospadias. *Urology*. 2002; 59: 584.
11. Giammusso B, Burrello M, Branchina A, Nicolosi F and Motta M: Modified corporoplasty for ventral penile curvature: description of the technique and initial results. *J Urol*, 2004; 171: 1209.
12. Peter N., Kelemen Z., Gergely B, Rusz A, Attila M., Romics I, Management of Congenital Penile Curvature, *The journal of urology* 2008; 179: 1495-1498.
13. Baskin LS, Erol A, Li YW Anatomy of the neurovascular bundle: is safe mobilization possible? *J Urol*, 2000; 164: 977-980.
14. Miller T A, Diagnostic Evaluation of Erectile Dysfunction. *Am Fam Physician*. 2000;61(1):95-104
15. Snodgrass W, Prietg J. Straightening ventral curvature while preserving the urethral plate in proximal hypospadias repair. *I Urol*, 2009;182(4 Suppl.):1720-5.
16. Braga et al, 2008. Hypospadias surgery and straightening maneuver of Ventral Curvature, submitted in *Campbell-Walsh urology*. 10thed. vol.4.2012. Saunders. Philadelphia . pp 3510..
17. Baskin et al, 1994. Hypospadias surgery and straightening maneuver of Ventral Curvature ,submitted in *Campbell-Walsh urology*. 10thed. vol.4.2012. Saunders. Philadelphia . pp 3510.
18. Mollard and Castagnola, 1994.Hypospadias surgery and straightening maneuver of Ventral Curvature ,submitted in *Campbell-Walsh urology*.10thed.vol.4.2012. Saunders. Philadelphia . pp 3510.
19. Kajbafzadeh et al, 2007.Hypospadias surgery and straightening maneuver of Ventral Curvature ,submitted in *Campbell-Walsh urology*.10thed.vol.4.2012. Saunders. Philadelphia . pp 3510.
20. Warwick et al, 1997.Hypospadias surgery and straightening maneuver of Ventral Curvature ,submitted in *Campbell-Walsh urology*.10thed.vol.4.2012. Saunders. Philadelphia . pp 3510.
21. Bracka, 1989; Thiounn et al, 1998; Van Der Horst et al, 2004; Greenfield et al, 2006. Hypospadias surgery and extent of Ventral Curvature ,submitted in *Campbell-Walsh urology*.10thed.vol.4.2012. Saunders. Philadelphia . pp 3509-11.
22. Paulo H. E., Lucon M. A., Sami A., Single relaxing incision to correct different types of penile curvature: surgical technique based on geometrical principles, *BJU international* 2004; 94: 1149.
23. Graziottin TM, Resplande J, Gholami SS, Lue TF: Peyronie's disease. *Int Braz J Urol*. 2001; 27: 326-40
24. Yutaro H., Kojima Y., Current concepts in hypospadias surgery, *International Journal of Urology* , 2008; 15, 651-664.
25. Baskin, L. S., Duckett, J. W., Ueoka, K., Seibold, J. and Snyder, H. M.: Changing concepts of

hypospadias curvature lead to more onlay island flap procedures. J Urol, 1994; 151: 191.

26. Baskin, L. S.:Editorial comment. Urology ,2002; 59: 586
27. YOSEF B Y, BINYAMINI J. , MATZKIN H. AND JACOB BEN-CHAIM, midline dorsal plication technique for penile curvature repair, the Journal of Urology, 2004; 172: 1368-69.