

# Anal Fissure: Is it becoming a medical disorder?

## Review Article

Ali Al-shaham, CABS\*. Kadhim Jawad, CABS\*\*, Serene A.A, MS\*\*\*

### ABSTRACT

An anal fissure which does not heal with conservative measures as sits baths and laxatives is a chronic anal fissure. Physiologically, it is the high resting tone of the internal anal sphincter that chiefly interferes with the healing process of these fissures. Until now, the gold standard treatment modality is surgery, either digital anal dilatation or lateral sphincterotomy. However, concerns have been raised about the incidence of faecal incontinence after surgery. Therefore, pharmacological means to treat chronic anal fissures have been explored.

A Medline and pub med database search from 1986-2012 was conducted to perform a literature search for articles relating to the non-surgical treatment of chronic anal fissure.

Pharmacological sphincterotomy using Glyceril trinitrate, Isosorbide dinitrate or calcium channel blockers are exciting alternative treatment, that relaxes the anal sphincter and, therefore, promote healing, the drawback of such medications are headache and poor compliance. With the introduction of Botulinum toxin as mean of chemical sphincterotomy, topical injection of Botulinum toxin reduces

the anal hypertonia which lasts for few months, allows the fissure to heal, thus eliminating the need for surgery without incidence of incontinence. Cure rates are over 60%, and the procedure can be repeated safely. Therefore, Botulinum toxin is a reasonable first-line management of chronic anal fissure and the relapses can be managed by surgery

**Keywords:** Non-surgical treatment of anal fissure, fissure in ano, sphincterotomy, botulinum toxin in anal fissures, glyceryl trinitrate. Chemical sphincterotomy, pharmacological sphincterotomy.

*Al-Kindy College Medical Journal 2014: Vol.10 No. 2  
Page: 1-4*

\*Al-Kindy Medical College-University of Baghdad/Iraq

\*\*Faculty of Medicine, Universiti Teknologi MARA Malaysia

\*\*\*School of Medicine, Tylor's University / Malaysia.

Received 24<sup>th</sup> Dec 2014, accepted in final 10<sup>th</sup> May 2015

Corresponding author: Ali Abbas Alshaham, Al-Kindy Medical

College, University of Baghdad, Iraq

e.mail: alialshaham@yahoo.com

**A**nal fissure is a longitudinal tear in the mucosa of anal verge upon passage of hard stool, and the patients usually present with fresh per rectal bleeding and anal pain during defecation. Although the acute anal fissures usually respond to conservative management with Sits baths and laxatives, the chronic one does not.<sup>1</sup> Until now, surgery has been necessary for treatment of these fissures, that do not respond to conservative therapy. However, there are exciting new advances in non-operative management that change the concept of management of this surgical disease into medical one, the introduction of many pharmacological agents that can treat anal fissures successfully without risk of anal incontinence and no hospitalization is required.

**Pathogenesis** In a patient with constipation, the passage of hard stool can injure the mucosa and skin of the anal canal. This anal injury triggers a spasm of the internal anal sphincter (IAS). A permanently elevated resting pressure of IAS impairs the intrasphincteric blood flow and consequently causing ischemia to the anoderm<sup>2</sup> that delays healing of these fissure, resulting in chronicity of these fissures as shown in Figure 1.

The reason for high incidence of posteriorly located anal fissures (90%)<sup>3</sup>, is that the posterior anus is already less perfused with blood than other parts of the anal canal and hence it is more vulnerable to sustain disease.<sup>4,5</sup>

The principle concept in the management of chronic anal fissure is reducing hypertonia of the IAS; It follows that a relief of IAS spasm will improve the blood supply to the anoderm and promote healing process.

**Methodology:** A Medline and pub med database was conducted during 26 years from 1986-2012 to perform a literature search for articles relating to the non-surgical treatment of chronic anal fissure.

**Surgical treatment:** The two most popular procedures are digital anal dilatation and lateral sphincterotomy.<sup>6</sup> In anal

dilatation, the surgeon stretches the sphincter to extend that the IAS becomes temporary paralyzed for several days. While in a lateral sphincterotomy, the surgeon divides the lowermost fibers of the IAS so that these fibers lose their spasm, and improve the blood supply with consequent healing of the fissure.<sup>7</sup>

After anal dilatation, fissures heal in 93% of patients. Nevertheless, because of the sphincter damage,<sup>8</sup> as many as 38% of patients can have transient incontinence<sup>9</sup> and a small number of patients have a degree of permanent incontinence.<sup>11</sup> Since anal dilatation may cause incontinence, many surgeons prefer lateral internal sphincterotomy, which often considered the procedure of choice for anal fissure. The sphincterotomy is simple to perform, and provides immediate relief of pain. Healing occurs in 96% of patients. Although incontinence is rare, it does occur, and may be permanent.<sup>10</sup> as shown in table 1.

### **Chemical sphincterotomy:**

Both surgical anal dilation and sphincterotomy are associated with irreversible damage to the IAS and the possibility of long term incontinence.<sup>9</sup> This complication of surgery can be quite distressing, and therefore researchers have investigated nonsurgical methods of reducing IAS spasm. They have discovered drugs that reduce this spasm and help in healing of the fissure, with no incidence of sphincter damage. The use of pharmacological agents for this purpose is called chemical sphincterotomy.

#### **1. Glyceril trinitrate and Isosorbide dinitrate:**

Glyceril trinitrate (GTN) and isosorbide dinitrate (ISD) relax smooth muscle. They reduce resting anal pressure, and improve blood flow to the region. The resting anal pressure falls immediately after topical anal application of GTN/ISD ointment.<sup>15, 16</sup> GTN ointment promotes healing of anal fissures in 33% to 88% of patients in different trials.<sup>17,18</sup> Moderate to severe headaches are commonly encountered

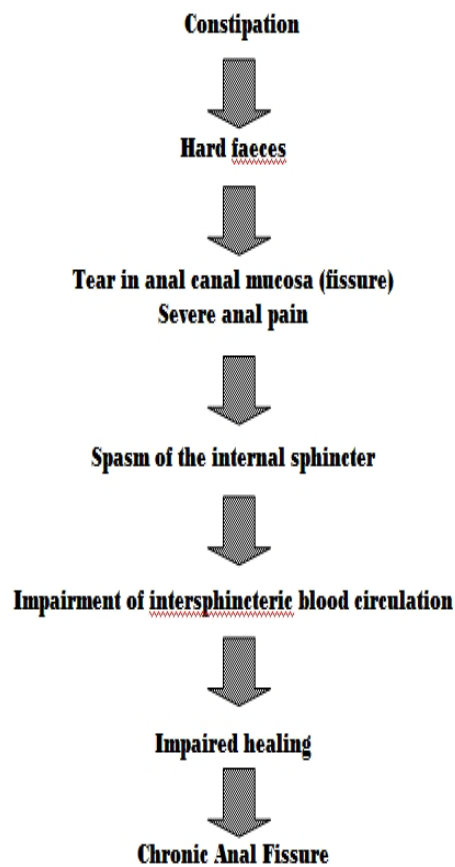


Figure 1: Pathogenesis of Fissure in Ano.

Table 1: The incidence of incontinence after lateral internal sphincterotomy.

Authors	No.	Incontinence to flatus%	Incontinence to faces %	Incidence of soiling %
Nyam and Pemberton <sup>10</sup>	487	6	1	8
Mélange et al <sup>11</sup>	76	17	11	9
Khubchandani and Reed <sup>12</sup>	829	35	5	22
Littlejohn and Newstead <sup>13</sup>	287	2	3	1
Hananel and Gordon <sup>14</sup>	312	1	1	1

with both drugs (80%patients)<sup>19</sup> and compliance is a major issue.<sup>20,21</sup> These side effects, along with tachyphylaxis, limit the utility of topical GTN/ISD ointment in the treatment of anal fissure.<sup>19</sup>

## 2. Calcium antagonists:

Nifedipine and diltiazem are calcium channel blockers. Topical application of both nifedipine<sup>22</sup> and diltiazem<sup>23</sup> have been evaluated. The reduction in anal pressure is a modest 28%, and the effect lasts for 3-5 hours after application.

### 3. Botulinum toxin:

Botulinum toxin is a lethal biologic neurotoxin released by *Clostridium botulinum*. It binds rapidly and strongly to presynaptic cholinergic nerve terminals, and prevents the release of acetylcholine into the neuromuscular junction.<sup>24</sup> This decreases the activity within parasympathetic and sympathetic cholinergic synapses, and produces a flaccid paralysis of skeletal muscle.

Botulinum toxin is a versatile tool and is used in disorders of striated muscles, e.g. spasmodic torticollis, strabismus, blepharospasm, and hemifascial spasm. The toxin can be used to weaken smooth muscle in the gastrointestinal tract<sup>25</sup> as in achalasia and infantile hypertrophic pyloric stenosis<sup>26</sup>.

In the treatment of anal fissure, botulinum toxin has greater clinical potential than GTN or the calcium antagonists. The advantage of using botulinum toxin injections in patients with anal fissure is that the ensuing reduction in anal pressure lasts for three or more months. This prolonged relaxation of the IAS allows the fissure to heal properly, thus eliminating the need for surgery without the risk of permanent incontinence<sup>27</sup> or hospitalization.

Typically, 0.4 ml (20 units) of botulinum toxin is injected around the fissure. Some patients may need re-injection after two months<sup>28</sup>. After injection of botulinum toxin, there is a significant decrease in resting anal pressure by 18-30%.<sup>28</sup> The therapeutic effect of sphincter relaxation occurs within a few hours after injection, relieving pain almost immediately. Another benefit over surgery is that no hospitalization, sedation or anesthesia is required during the procedure. It is safe, easy to perform constantly good cure rate. A transitory incontinence for flatus occurs in about 3% of patients<sup>28</sup>. As shown in Table 2.

**Table 2:** Treatment of chronic anal fissure using botulinum toxin injection

Author	No.	Temporary incontinence (%)	Healing rate (%)
Maria et al. <sup>29</sup>	57	2	68
Fernandez et al. <sup>30</sup>	76	3	67
Minguez et al. <sup>31</sup>	69	0	63

In a randomized trial, Nasr et al<sup>32</sup> showed that fissure healing occurred in 25/40 patients after use of botulinum toxin, as compared to 36/40 patients after lateral sphincterotomy. Permanent incontinence does not seem to occur with the use of botulinum toxin.

We believe that botulinum toxin injection should be the first line treatment in patients with chronic anal fissure before surgery is considered. Over sixty percent of patients will heal without the morbidity or side effects of surgery.

In Conclusions, Although surgical sphincterotomy is the gold standard procedure in patients with fissure in ano, the use of pharmacological means to treat chronic anal fissure is an interesting alternative. Atrial with botulinum toxins therapy is appropriate before any surgery for the following advantages: it is safe, effective, less expensive and easier to perform as an outpatient procedure and does not require anesthesia or hospitalization. No adverse effects or permanent sphincter damage. Botulinum toxin is strongly indicated in patients having high surgical risk and patients with high risk of future incontinence.

### References:

- Ellis H, Calne R, Watson C. Anal fissure. In *Lecture Notes: General Surgery*, 11th edition, Blackwell, Massachusetts, 2006, p219-231.
- Gibbons CP, Read NW. Anal hypertonia in fissures: cause or effect? *Br J Surg*. 1986;73:443-5.
- Maria G, Brisinda G, Bentivoglio AR, Cassetta E, Gui D, Albanese A. Botulinum toxin injections in the internal anal sphincter for the treatment of chronic anal fissure: long-term results after two different dosage regimens. *Ann Surg* 1998;228:664-9.
- Klosterhalfen B, Vogel P, Rixen H et al. Topography of the inferior rectal artery: A possible cause of chronic, primary anal fissure. *Dis Colon Rectum* 1989;32:43-52.
- Schouten WR, Briel JW, Auwerda JJ. Relationship between anal pressure and anodermal blood flow. The vascular pathogenesis of anal fissures. *Dis Colon Rectum* 1994;37:664-9.
- Schouten WR, Briel JW, Auwerda JJ et al. Anal fissure: New concepts in pathogenesis and treatment. *Scand J Gastroenterol Suppl* 1996;218:78-81.
- Isbister WH, Prasad J. Fissure in ano. *Aust N Z J Surg* 1995;65:107-8.
- Schouten WR, Briel JW, Auwerda JJ et al. Ischaemic nature of anal fissure. *Br J Surg* 1996;83:63-5.
- Speakman CT, Burnett SJ, Kamm MA et al. Sphincter injury after anal dilatation demonstrated by anal endosonography. *Br J Surg* 1991;78:1429-30.
- Lewis TH, Corman ML, Prager ED et al. Long-term results of open and closed sphincterotomy for anal fissure. *Dis Colon Rectum* 1988;31:368-71.
- Nyam DC, Pemberton JH. Long-term results of lateral internal sphincterotomy for chronic anal fissure with particular reference to incidence of fecal incontinence. *Dis Colon Rectum* 1999;42:1306-10.
- Melange M, Colin JF, Van Wymersch T et al. Anal fissure: Correlation between symptoms and manometry before and after surgery. *Int J Colorectal Dis* 1992;7:108
- Khubchandani IT, Reed JF. Sequelae of internal sphincterotomy for chronic fissure in ano. *Br J Surg* 1989;76:431-4.
- Littlejohn DR, Newstead GL. Tailored lateral sphincterotomy for anal fissure. *Dis Colon Rectum* 1997;40:1439-42. 34.
- Hananel N, Gordon PH. Lateral internal sphincterotomy for fissure-in-ano-Revisited. *Dis Colon Rectum* 1997;40:597-602.
- Loder PB, Kamm MA, Nicholls RJ et al. 'Reversible chemical sphincterotomy' by local application of glyceryl trinitrate. *Br J Surg* 1994;81:1386-9.
- Kua KB, Kocher HM, Kelkar A et al. Effect of topical glyceryl trinitrate on anodermal blood flow in patients with chronic anal fissures. *Aust N Z J Surg* 2001;71:548-50.
- Gorfine SR. Treatment of benign anal disease with topical nitroglycerin. *Dis Colon Rectum* 1995;38:453-6.
- Lund JN, Scholefield JH. A randomised, prospective, doubleblind, placebo-controlled trial of glyceryl trinitrate ointment in treatment of anal fissure. *Lancet* 1997;349:11-4.
- Richard CS, Gregoire R, Plewes EA et al. Internal sphincterotomy is superior to topical nitroglycerin in the treatment of chronic anal fissure: Results of a randomized, controlled trial by the Canadian Colorectal Surgical Trials Group. *Dis Colon Rectum* 2000;43:1048-57.
- Altomare DF, Rinaldi M, Milito G et al. Glyceryl trinitrate for chronic anal fissure-Healing or headache? Results of a multicenter, randomized, placebo-controlled, double-blind trial. *Dis Colon Rectum* 2000;43:174-9.
- Palazzo FF, Kapur S, Steward M et al. Glyceryl trinitrate treatment of chronic fissure in ano: One year's experience with 0.5% GTN paste. *J R Coll Surg Edinb* 2000;45:168-70.
- Lysy J, Israelit-Yatzkan Y, Sestiere-Ittah M, Keret D, Goldin E. Treatment of chronic anal fissure with isosorbide dinitrate: long-term results and dose determination. *Dis Colon Rectum*. 1998;41:1406-10.

24. Antropoli C, Perrotti local use in conservative treatment of anal fissures: preliminary results of a multicenter study. *Dis Colon Rectum*. 1999;42:1011-5.
25. Carapeti EA, Kamm MA, Evans DE, Phillips RKS. Diltiazem lowers resting anal sphincter pressure - a potential low side-effect alternative to glyceryl trinitrate for fissures. *Gastroenterology*. 1998;114:A7.
26. Westfall TC, Westfall DP. Neurotransmission: the autonomic and somatic motor neuron systems. In: Brunton LL, Lazo JS, Parker KL, eds. *Goodman & Gillman's, The Pharmacological Basis of Therapeutics*, 11th edition. New York: McGraw-Hill, 2006:137-81.
27. Albanese A, Colosimo C, Carretta D. Botulinum toxin as a treatment for blepharospasm, spasmodic torticollis and hemifascial spasm. *EurNeurol* 1992;32:112-7.
28. Pasricha PJ, Ravich WJ, Hendrix TR et al. Intrasphincteric botulinum toxin for the treatment of achalasia. *N Engl J Med* 1995; 332:774-778.
29. Mason PF, Watkins MJG, Hall HS, Hall AW. The management of chronic fissure in ano with botulinum toxin. *J R CollSurgEdinb* 1996; 41:235-238.
30. Maria G, Cassetta E, Gui D et al. A comparison of botulinum toxin and saline for the treatment of chronic anal fissure. *N Engl J Med* 1998;338:217-20.
31. Fernandez LF, Conde FR, Rios RA et al. Botulinum toxin for the treatment of anal fissure. *Dig Surg* 1999;16:515-8.
32. Nasr M, Ezzat H, Elsebae M. Botulinum Toxin Injection Versus Lateral Internal Sphincterotomy in the Treatment of Chronic Anal Fissure: A Randomized Controlled Trial. *World J Surg* 2010;34:2730-4