

# Multiple hydatid cysts in lungs, liver and spleen

\*Ayad J. Matar M.B.Ch.B. C.A.B.S \*\*Saad M. Hadbool M.B.Ch.B

## Abstract

We presented here a 25years old lady with a multiple hatdtid cysts in lung and liver and spleen in large number in each organ. Which regarded inoperable and difficult to treated.We use medical treatment with antihelimenthes drugs in new regime and

follow-up over 1year clinically, laboratory investigations, U/s and CT.scan. There was good disappearance of liver and spleen cysts with very good response in lungs

**Keywords:** hydatid cysts, liver, spleen

**Al – Kindy Col Med J 2013; Vol. 9 No. 1 P:**

## Introduction:

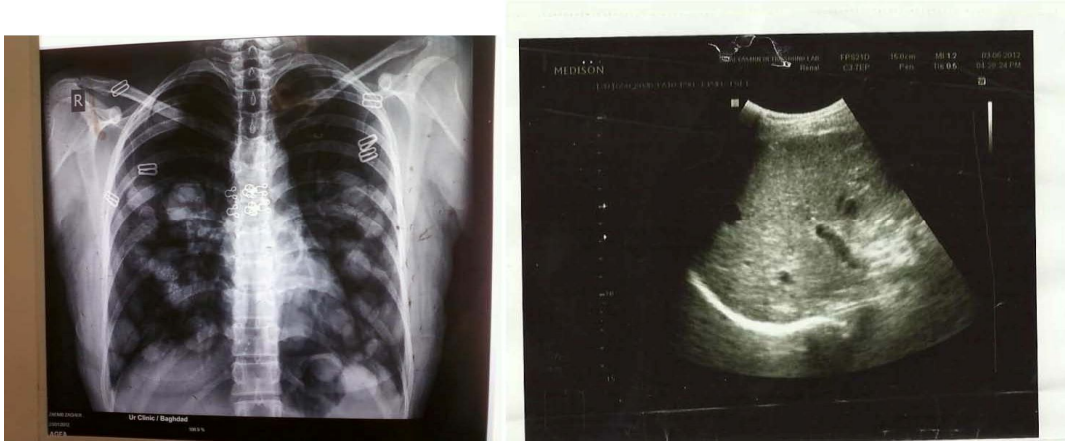
Hydatid disease is due to the larval or cyst stage of infection by the tapeworm *Echinococcus granulosus*, which lives in the dog.Humans, sheep, and cattle are intermediate hosts,the infected ova-containing feces of the dog contaminate grass and farmland, and the ova are ingested by sheep, pigs, and humans,the ova have chitinous envelopes that are dissolved by gastric juice,the liberated ovum burrows through the intestinal mucosa and is carried by the portal vein to the liver, where it develops into an adult cyst, most cysts are caught in the hepatic sinusoids, and 70% of hydatid cysts form in the liver, a few ova pass through the liver and are held up in the pulmonary capillary bed or enter the systemic circulation, forming cysts in the lung, spleen, brain, or bones, hydatid disease is most common in sheep-raising areas, and the Middle East, unless the cysts are small or the patient is not a suitable candidate for surgical resection, the treatment of hydatid disease is surgically based because of the high risk of secondary infection and rupture, medical treatment with albendazole relies on drug diffusion through the cyst membrane, the concentration of drug achieved in the cyst is uncertain but is better than that of

mebendazole, and albendazole can be used as initial treatment for small, asymptomatic cysts<sup>(1)</sup>.

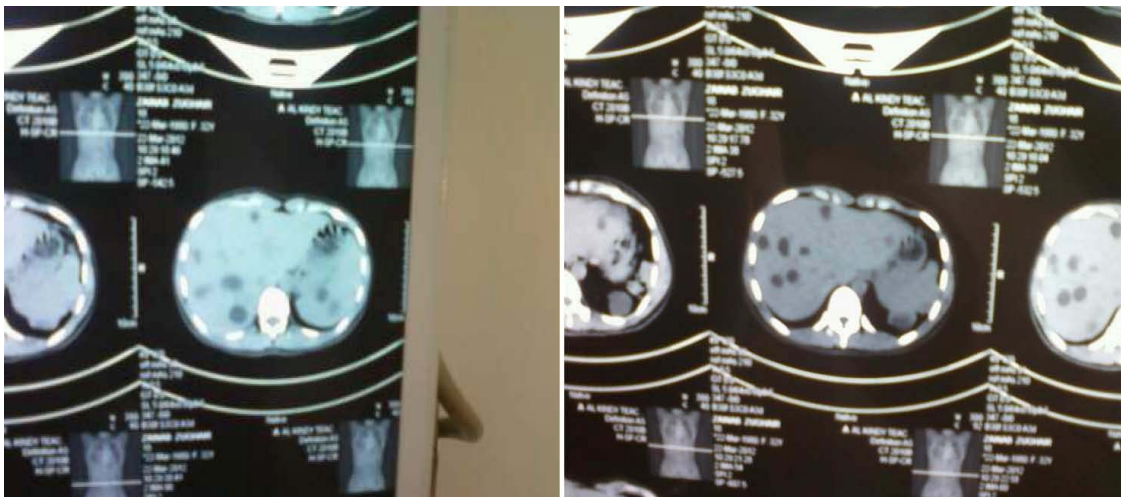
## Case Report:

A 25years old female patient had 2children,presented productive cough and Rt.hypochondrial pain for more than one month associated with low grade fever and fatigability. **CXR:** show multiple bilateral cystic lesions in both lung fields, some show fluid level (**figure1**). **U/S:** Liver large size due to multiple cystic lesions(about 30) size between(15\_29mm),thin wall, clear fluid, features go with multiple hydatid cysts of liver, normal portal vessels normal billiary tree, normal CBD,no dilatation, no stone. Spleen mildly large due to (5cysts) similar to that of liver size between (19\_25mm).(**figure2**).**CT.scan:** There is multiple bilateral relatively thin walled cystic lesions seen in the both lung fields, some show fluid level inside associated with fluffy consolidations and small left lower small nodules seen. Liver: normal size, texture, multiple thin walled regular cystic lesions seen. Spleen: normal size, texture, multiple thin walled regular cystic lesions seen. (**figure3**).

**Figure 1** CXR showing multiple bilateral hydatid cyst in both lungs  
**Figure 2** U/S showing multiple hydatid cysts in liver.  
**Figure 3** showing Liver: multiple thin walled regular cystic lesions seen. Spleen: multiple thin



walled regular cystic lesions seen.



**Blood Inv.:** WBC=14.6, Eson.19%, HGB=9.74 g/dl, ESR=105, BilD=0.2 BiliT=0.4 Alkp=230 ALT=66 AST=45 U/L, pLT 550, Blood film: Anemia of chronic disease, ELISA strongly positive for hyditosis.

patient treated by antibiotic for chest infection, tonics for anemia and by Albendazol 400 mg bid+praziquantal 600mg

once daily in a cycle for 28 days followed by 14 days off for 5 cycle during that patient followed regularly by clinical examination, labratory and U/S investigational end of the fifth cycle the liver and spleen are completely cured of any cysts, also lung show effective response regarding the number and size of the cysts as shown in figures (4, 5).

Figure 4 CXR after treatment show disappearance of most of

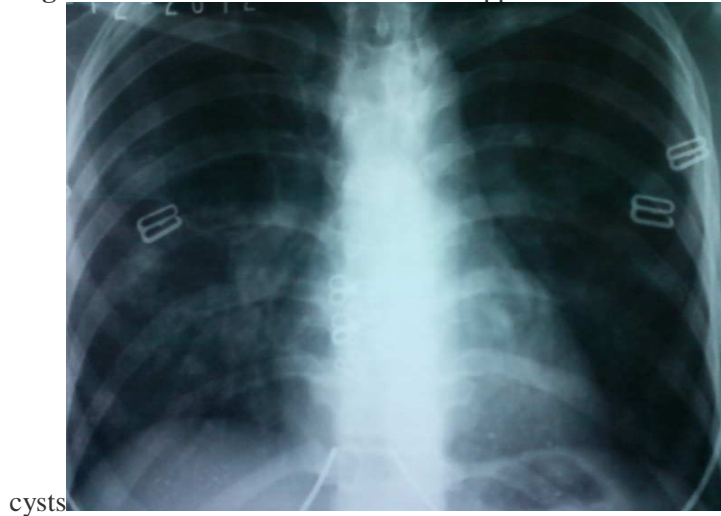
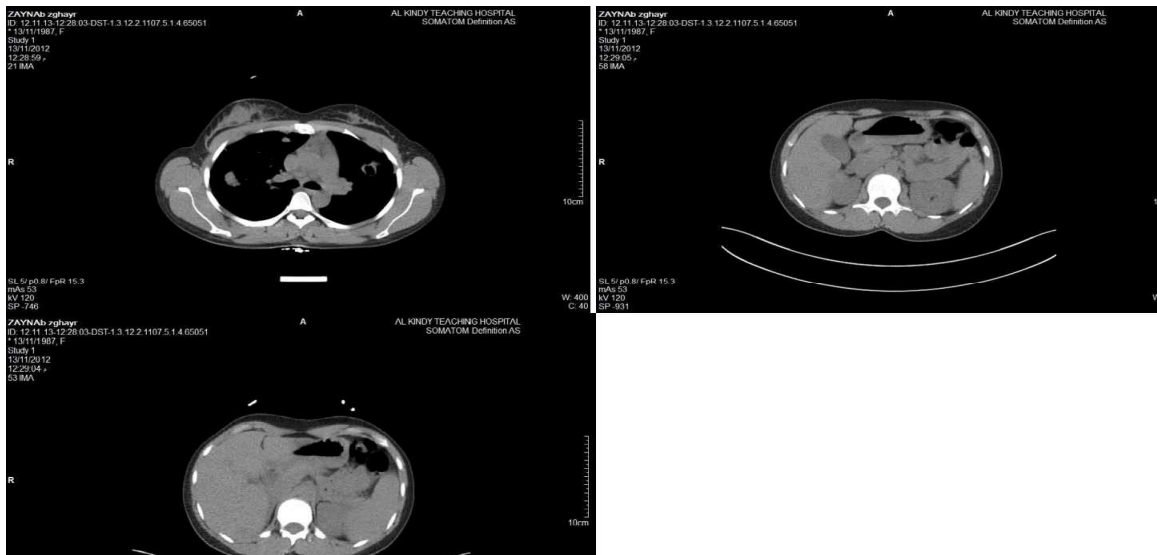


Figure 5 CT scan of chest and abdomen

Her blood investigation at the end of course



as follow HB 11.5 G/dl ,WBC 5400 Cell/cmm,Eson.2.04%, PLATLETS 271000/cmm, ESR 15, Alkp.73 IU/L, AST 16, ALT 11, BilD<0.1, BiliT 0.1

**Discussion:**

As the parasite can colonise virtually every organ in the body, the condition can be protean in its presentation, the liver is the organ most often affected, the lung is the next most common the parasite can affect any organ or several organs in the same patient. Chemotherapy is indicated in patients with primary liver or lung cysts that

are inoperable (because of location or medical condition), patients with cysts in 2 or more organs, and peritoneal cysts. Albendazole is significantly more effective than mebendazole in the treatment of liver cysts. Benzimidazole treatment alone requires prolonged administration over many weeks, with an unpredictable outcome in terms of response rates in individuals. Continuous treatment is preferred and has been administered for periods of up to 2 years without significant side effects. The optimal period of treatment ranges from 3-6 months, with no further increase in the incidence of adverse effects if this period is prolonged. Limited data are available on the weekly use of praziquantel, an isoquinoline derivative, at a dose of 40 mg/kg/wk, especially in cases in which intraoperative spillage has occurred. Praziquantel has recently been suggested, administered additionally once per week in a dose of 40 mg/kg during treatment with albendazole. However, available data are limited.

Albendazole decreases ATP production in worm, causing energy depletion, immobilization, and, finally, death. Praziquantel (Biltricide) Increases cell membrane permeability in susceptible worms, resulting in loss of intracellular calcium, massive contractions, and paralysis of musculature. In addition, produces vacuolization and disintegration of schistosome tegument. This is followed by attachment of phagocytes to parasite and death.

**References:**

- 1). Bernard M. Jaffe, MD. The liver. In: Schwartz's Principles of Surgery, 9th Ed. The McGraw-Hill Companies. 2010:p1116.
- 2). P. Ronan O'Connell. Surgery in Tropics. In; Bailey & Love's SHORT PRACTICE of SURGERY, 25<sup>th</sup> ed. Edward Arnold, 2008:p56.
- 3). Enrico Brunetti, MD. Echinococcosis Hydatid Cyst Treatment & Management. emedicine Medscape. Com / article / 216432.19 Oct 2011.
- 4). Stojkovic M, Zwahlen M, Teggi A, Vutova K, Cretu CM, Virdone R, et al. Treatment response of cystic echinococcosis to benzimidazoles: a systematic review. *PLoS Negl Trop Dis*. Sep 29 2009; 3(9):e524.
- 5). Liu Y, Wang X, Wu J. Continuous long-term albendazole therapy in intraabdominal cystic echinococcosis. *Chin Med J (Engl)*. Sep 2000; 113(9):827-32.
- 6). [Guideline] Brunetti E, Kern P, Vuitton DA, Expert consensus for the diagnosis and treatment of cystic and alveolar echinococcosis in humans. *Acta Trop*. Apr 2010; 114(1):1-16.
- 7). Bygott JM, Chiodini PL. Praziquantel: neglected drug? Ineffective treatment? Or therapeutic choice in cystic hydatid disease?. *Acta Trop*. Aug 2009; 111(2):95-101.

\*From Department of Surgery Al Kindy Teaching Hospital: Correspondence Address to: Dr Ayad J.Matar E-mail: ayad\_matar@yahoo.com \*\*Resident, Department of surgery, Al\_Kindy Teaching Hospital

