

A typical clinical presentation of molluscum contagiosum in Iraqi patients; clinical descriptive study

*Dr. Maytham M. Al-Hilo MBChB, FICMS DV; * Dr. Mohammed Y. Abbas , MBChB, FICMS DV ;Dr. Ahlam I. Alwan, MBChB, DVD, DLM*

Abstract

Background Molluscum contagiosum is skin disease caused by the molluscum contagiosum virus (MCV) usually causing one or more small dome shaped umbilicated papules with symptoms that maybe self-resolve. MCV was once a disease primarily of children, but it has evolved to become a sexually transmitted disease in adults. It is believed to be a member of the pox virus family. In addition to the classic presentation of the disease; it can also come in different clinical forms that simulate large number of dermatological disease.

Objective: To study different clinical forms of Molluscum contagiosum presentation in different age groups of Iraqi patients.

Method: This clinical descriptive study was performed in the outpatient department of

Dermatology and Venereology : Al-Kindy Teaching Hospital in Baghdad from August 2010 - October 2011A total of three hundred and thirty Patients (180 female sand150 males) recruited in this study diagnosed as Molluscum contagiosum on different sites ; both classical and non classical presentation were studied.

Results: Twenty eight patients (8.48%) out of the 330 patients (14 male and 12 female) showed atypical clinical presentation, while 302 (91.52%) patients showed typical presentation.

Conclusion: Molluscum contagiosum can presented with either classic or non classic presentation mulating many dermatological disease.

Keywords: Molluscum contagiosum. Atypical presentation

Al - Kindy Col Med J 2012 ; Vol .8 No. (2) p: 18-27

Introduction

Molluscum contagiosum is a common benign viral infection of the skin caused by Molluscipox virus, a member of the Poxviridae family. The virus was first described by Bateman in the beginning of the 19th Century, who also later assigned the name to it¹. The virus is distinct from other poxviruses in that it causes spontaneously regressing, umbilicated tumors of the skin rather than pox like vesicular lesions, the virus is found world wide with higher distribution in tropical countries. The disease is transmitted primarily through direct skin contact with an infected individual, although fomites have been suggested as another source of infection².

The average incubation period of the disease is between 2 and 7 weeks with a range extending out to six months. The disease is endemic with a higher

incidence within institutions and communities where overcrowding, poor hygiene and poverty favor its spread². The worldwide incidence of the disease is estimated to be between 2% and 8%³. Over the last three decades the incidence of infection has been increasing, mainly as a sexually transmitted disease, because of the concurrent HIV infection; it has been reported that between 5% and 20% of HIV patients have MCV^{4, 5, 6}. The disease is more common in children with the lesion involving face, trunk, and extremities. In adults, the lesions are most commonly found near the genital region. The clinical appearance of Molluscum contagiosum in most cases is diagnostic. Though it can not be cultured in the laboratory, the histological examination of a curetted or biopsied lesion can also aid in the diagnosis in cases that are not clinically obvious. Other modalities by which the virus can be demonstrated are electron microscopy, immunohistochemical

methods using polyclonal antibody and in-situ hybridization for MCV DNA.^{7,8}

There are four main subtypes of molluscum contagiosum: MCV I, MCV II, MCV III, and MCV IV^{9,10} All subtypes cause similar clinical lesions in genital and nongenital regions. Studies show MCV I to be more prevalent (75%–90%) than MCV II, MCV III, and MCV IV, except in immunocompromised individuals^{11,12} There are, however, regional variations in the predominance of a given subtype and differences between individual subtypes in different countries.¹³

This study was designed to shed light on different clinical presentation of this disease.

Method

This clinical descriptive study was performed in the Outpatient Department of Dermatology and Venereology in Al-Kindy Teaching Hospital in Baghdad during the Period between August 2010 - October 2011.

A total of three hundred and thirty patients 180 females(54.54%) and 150 males (45.46%) were recruited in this study diagnosed as Molluscum contagiosum on different sites of their body, The patients administered questionnaire elicited information on their age ,sex, site and duration of the lesion, and examination of the patient include number and size of lesion, morphology of lesion whether it is classical or simulate any other dermatological lesions also the frequency of attacks before (whether it was the first attack, second attacks or recurrent (if recurred more than three times before), positive family history. association with other disease

(immunosuppressive disease, dermatitis, or secondary bacterial disease) or other sexually transmitted disease), The patients were examined fully and diagnosed as a case of Molluscum contagiosum depending on a clinical aspect, and all were photographed by using a digital camera. All cases with non classical presentation were subjected to excisional biopsy and send for histopathological study.

Descriptive statistics were undertaken using Microsoft Excel.

Results:

From August 2010 - October 2011, three hundred and thirty patients (180 females and 150 males) attend dermatology and venereology out patient clinics in AL – KINDY Teaching Hospital in Baghdad diagnosed as molluscum contagiosum on different site of their bodies.

Age and Sex distribution:

Out of 330 patients, (180) were females their ages range between one year and sixty five years with median of 19 years, and 150 male their age vary between one year and forty six year with median of 19 years.

Patients below 10 years of age were 162(49.9 %)(63 male patients and 99 female

Patients between 10-20 years were 50(15.15%) (25 male and 25 female)

Patients over the age of 20 were 118(35.75%) (70 male and 48 female)

Distribution of lesions

The distribution of lesions according to body site is shown in table 1.

Table. 1 distribution of lesions of Molluscum contagiosum according to body site

Site of body	Number of lesion	percentage
Head and neck	258	78.18%
Upper extremity	24	7.27%
Lower extremity	6	1.81%
Chest	14	4.24%
Back	-	0%
Genital	33	10%
Total	335	100%

Out of the 33 (10%) cases reported with genital lesions, 9 (2.7) patients were young children 2-3 years olds while 24 (7.2%) were adults (9--15 females). No sexually transmitted disease was reported in association with Molluscum on genital region.

The size of the lesions

The size of the lesions was equal or up to 6mm in 310(93.93%) patients . While 23(6.9%) patients show Molluscum of 6mm or more which was especially seen on the face.

The number of lesions

Table 2 shows the number of lesion for all patients

Table 2. Number of lesions in patients with Molluscum contagiosum

Number of lesions	Number of patients	percentage
One	76	23.0%
2-3	106	32.12%
More than three lesion	148	44.48%
Total	330	100%

Frequency of attacks:

Table 3 shows the frequency of attacks according to patient's number.

Table 3. The frequency of attacks

Type of attack	Number of patients	percentage
First attack	222	67.27%
Second attack	100	30.30%
More than two	8	2.42%
Total	330	100%

Duration period

The duration of the disease varied between two weeks and seven months. Sixteen(4.8%) patients (4.8%) gave duration of up to two weeks, 232 (70.30%) patient of two weeks to four weeks and 82 (24.84%) patients with duration of more than four weeks.

Family history

One hundred twenty three (37.27%) patients had negative family history
Atypical clinical presentation

while 207 (62.72%) patients gave positive family history when one or more member in family or very close relatives had the same skin disease.

Typical clinical presentation

From a total of 330 patients 304 (91.52%) patients 168 female and 136 male showed classic distribution of dome shape papule of size vary between 1mm and 15mm in different site of the body.

Twenty eight (8.48%) patients out of the 330 patients (16 male and 12 female) show atypical clinical presentation.

Six (1.8%) patients showed herpes simplex like figure 1a, with grouped papules on left side of neck associated with mild itching of forty days duration with positive family history of Molluscum contagiosum.

Six patients (1.8%) showed lesion similar to plane warts figure 1b, with small flat papule on the chin of eleven years old child with three more dome shaped umbilicated papules on forehead of one month duration.

Three (0.9%) patients showed keratoacanthoma-like presentation figure 1c, which show 12mm nodule with central keratotic crust of six weeks duration on the lateral side of the nose in forty five years old male patient with positive family history of Molluscum contagiosum, the other two patients were female with one with nodule located on cheek and other on upper lip.

One (0.3%) patient looks like stye figure 1d, with associated conjunctivitis on same site.

One (0.3%) patient lesion looks like skin tag figure 2 a, with skin colored slightly pedunculated papule of 3mm size on left lower lid of twenty eight years old female of one month duration.

One (0.3%) patient look with abscess like figure 2b with dusky erythematous nodule of (3cm X 2cm) size on the left lower lid of a 7 year's old girl associated

with classic Molluscum papules 2-3 mm size on the forehead, cheek and upper neck.

One (0.3%) patient with giant condyloma of Bushckie and Lowneshtein figure 2c which was reported in two years old boy on perianal region.

Two (0.6%) patients showed horn like lesion figure 2d, one was a child three years old with projecting papule on left lower lid, the other was a child six years old with papule on forehead.

One (0.3%) patient with BCC likes lesion figure 2e with cystic nodule with dilated blood vessels across the surface lesion on the lower lip of sixty four years old lady of two months duration.

One (0.3%) patient with Pyogenic granuloma likes fig 3a on the chin of forty seven years old lady.

One (0.3%) patient with keloid likes fig 3b.

One (0.3%) patient with sebaceous cyst likes figure 3e.

One (0.3%) patient with fibroma likes.

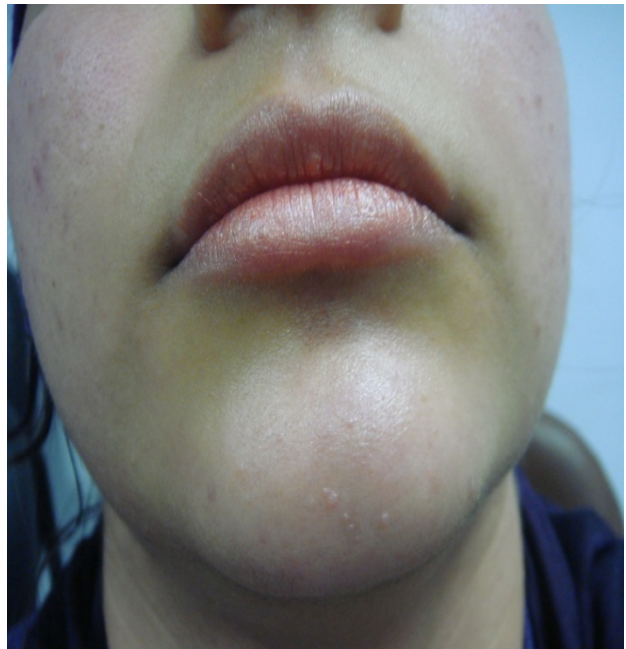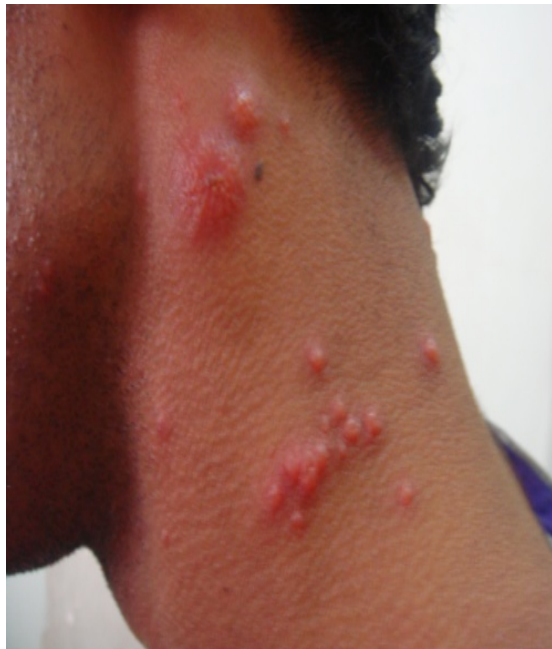One (0.3%) patient with exophytic warty lesion likes above the right eyebrow of eleven years old child of three weeks duration.

One (0.3%) patient looks with leishmania like lesion on right cheek of thirty four years old lady with history of seven months and she received many topical and systemic antibiotics with no benefit

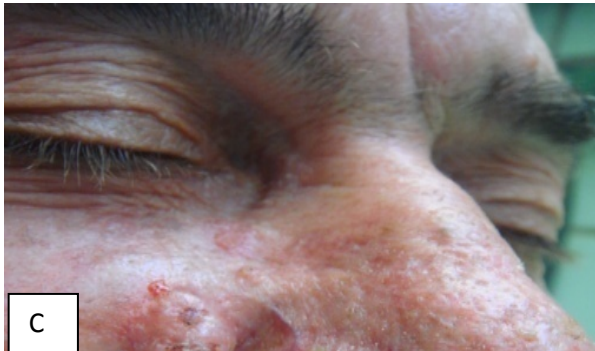Table 3: The atypical presentation of molluscum lesions

Lesion look like	No.of patients	percentage
Herpes simplex like	6	1.8%
plane warts like	6	1.8%
keratoacanthoma like	3	0.9%
stye like	1	0.3%
skin tag like	1	0.3%
abcess like	1	0.3%

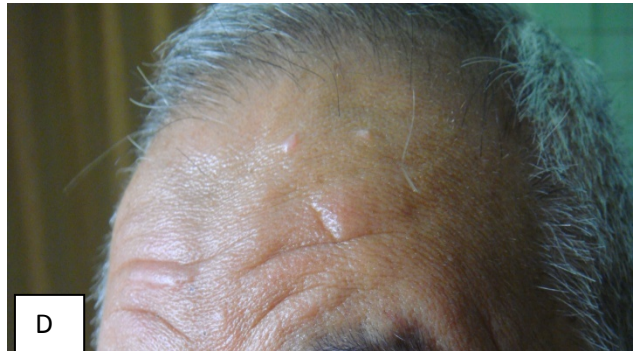condyloma of Busckie and Lowneshtein	1	
horn like	2	0.6%
Basal cell carcinoma like	1	0.3%
Pyogenic granuloma like	1	0.3%
keloid like	1	0.3%
sebaceous cyst like	1	0.3%
fibroma like	1	0.3%
exophytic warty lesion	1	0.3%
Leishmania like	1	0.3%
Total	28	8.48%



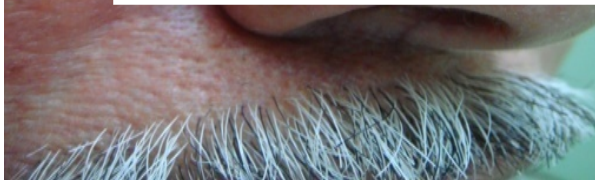A



B



C

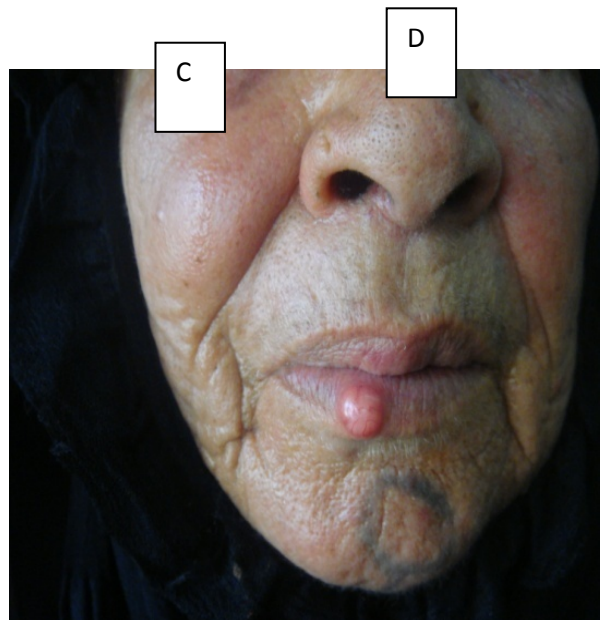


D

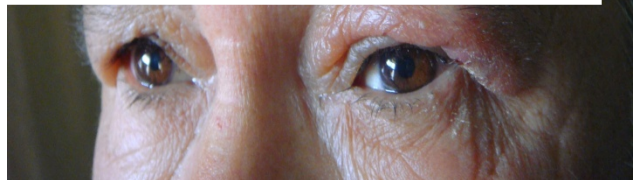
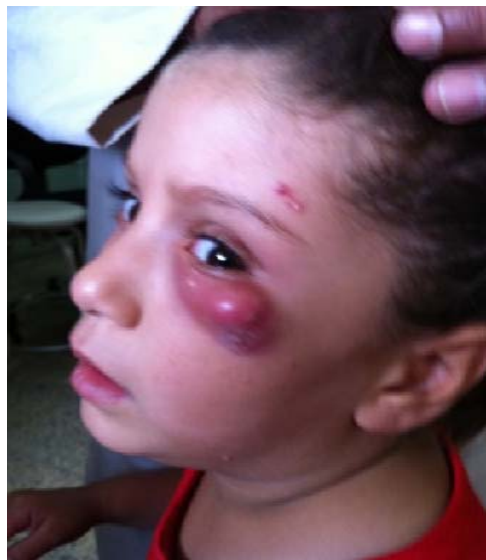
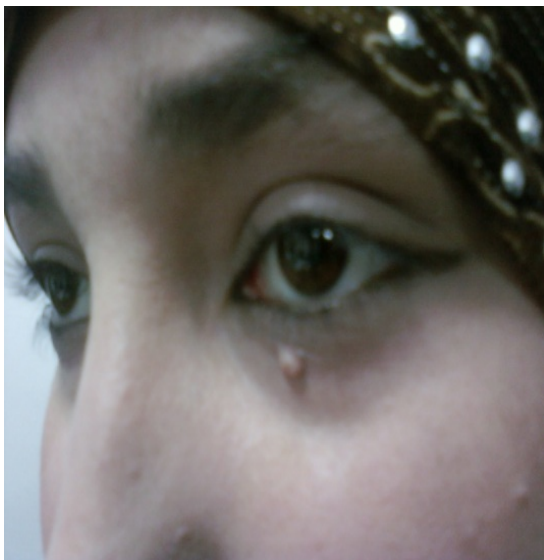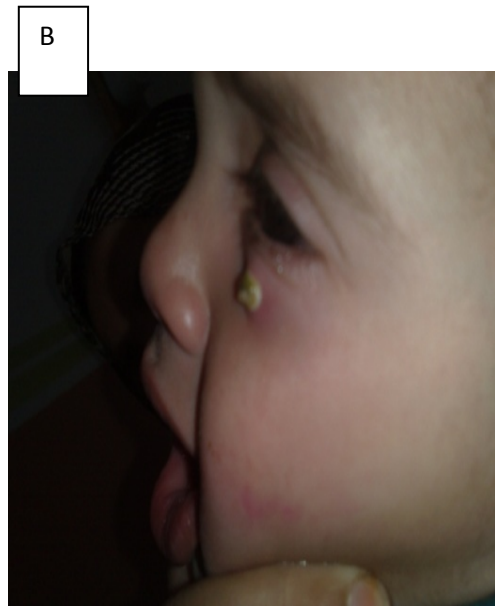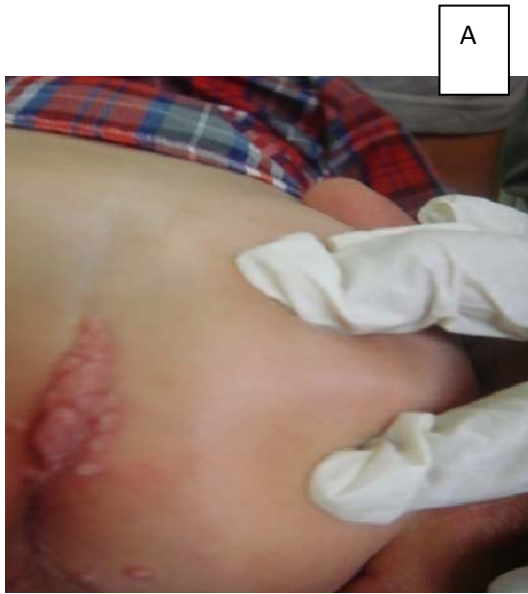Fig.1 A Herpes simplex like.B plane warts like.C keratoacanthoma like.D styelike





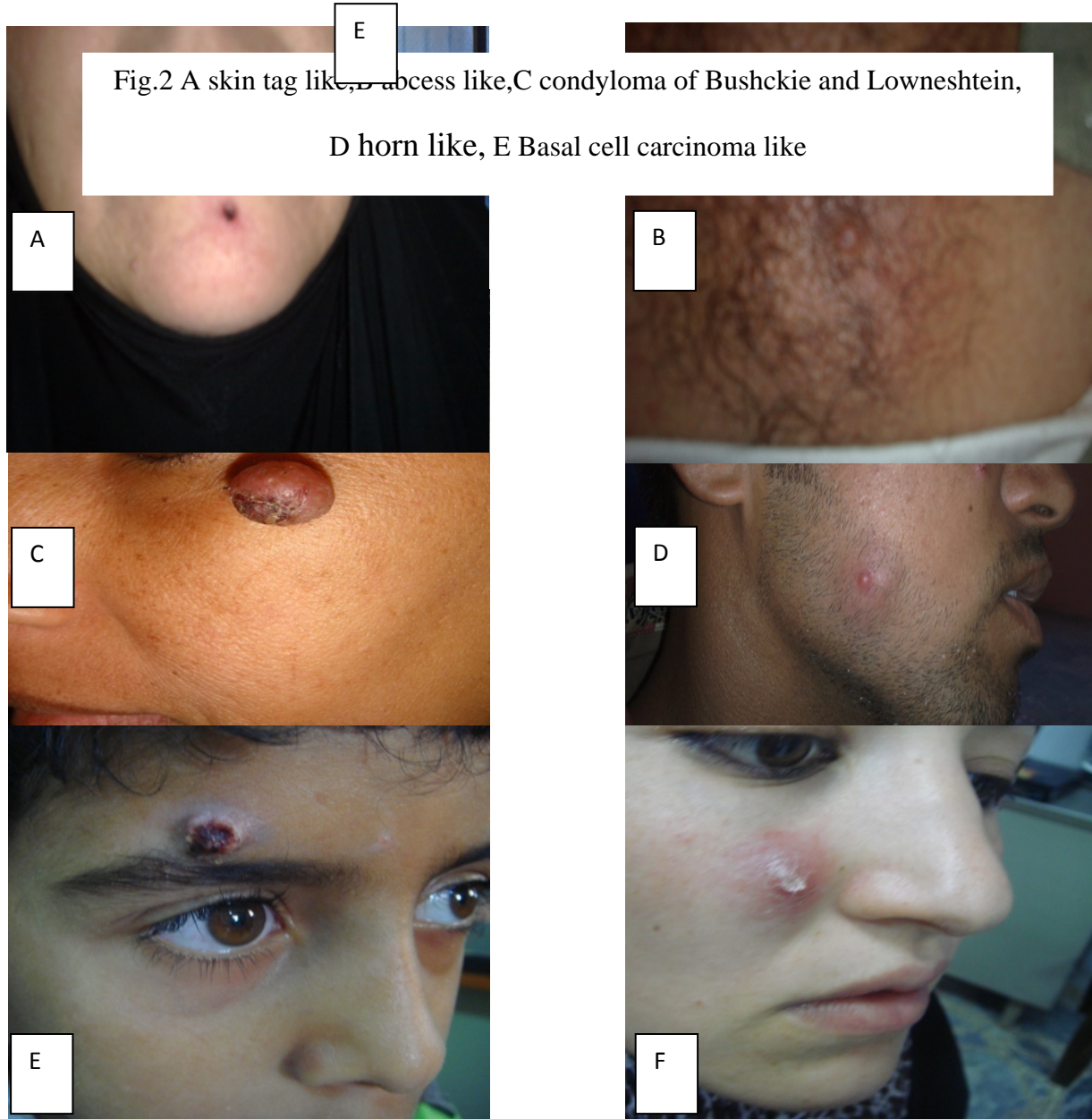


Fig.3 A Pyogenic granuloma like, B keloid like, C fibroma like D sebaceous cyst like, E Exophytic warty lesion F leishmania like lesion.

Sebaceous cyst like

Discussion

Molluscum virus infection occurs worldwide and appears to be specific to human. Although the disease can affect any age group but it generally affect young children¹⁴

In this study we found that patients below ten years of age were the predominant affecting age group 162 (49.9%) patients (63 male and 99 female) out of 330 patients, this affection rate differ from what has been reported in the united state in one study which show that the rise in Molluscum appears to be parallel the overall rise in sexually transmitted disease while the prevalence rate in children is of less than 5%.¹⁵ and our result is comparable to Childhood molluscum contagiosum in Papua New Guinea, Fiji, and certain parts of Africa, as they found that the peak incidence of the disease is among children younger than 5 years, with a prevalence of approximately 25%.¹⁶

Most of the lesions were seen distributed on head and neck (78.18%) and least on lower extremity 1.81% this agree with the common distribution of disease on the face, trunk, and extremity.¹⁷

Genital lesion was seen in 10% of patients, 24 (7.2%) were adults (9 male and 15 female) and there was no reported association with sexually transmitted disease with such patients, while genital lesion in young children was reported in only nine patients (2.7%) their ages were between two and three years of age with no associated child abuse signs.

This agrees with. Becker TM *et al*, who found that genital and perianal lesion can develop in children and are rarely associated with sexually transmission in this population¹⁸.

The size of lesion reported in this study was up to 6 millimeter in diameter in

310 patients (93.93%) while 23 (6.9%) show Molluscum with size over 6mm in diameter seen mostly on the face with central umbilication this agree with what has been reported by Brown J *et al*.¹⁹

Patients who present with multiple lesions (44.48%) were more than those who have only single lesion (23.0%), Or 2-3 lesion (32.12%) this goes with what has been written in text that number of lesion may vary from few to more than 100 lesions¹⁷.

Those who develop the disease for the first time were (67.27%), while those who develop second attack (30.30%) and those with more than two attacks were (2.42%), this is probably because of incomplete treatment of the disease or reinfection from other infected contact which could be in the same family or close contact with other infected individuals.

The duration of the disease in (70.3%) was between two to four weeks, (24.84%) with duration of more than four weeks, while only (4.8%) gave duration of up to two weeks these finding with the course of the disease which is often prolong course and it may persist for months to years¹⁴.

As the disease is contagious so patient with positive family history were more (62.72%), while those with negative family history was found to be (37.27%) this probably related to subclinical spread of infection that agree with the Australia study which support that subclinical or mild unrecognized disease do exist in population.¹⁴

Typical presentation of flesh color papule that begins as small papule and gradually enlarge in size with dome surface and central umbilication was seen in 304 patients (92.12%) while only Twenty six patients (7.78%) show atypical presentation resembling Herpes

simplex, plane warts, keratoacanthoma, stye, skin tag, abscess like, condyloma of Bushckie and Lowneshtein, horn like, BCC ,and Pyogenic granuloma like.

The disease can simulate variety of common dermatological skin diseases or present with fulminant presentation ^{19,20}. To the best of our knowledge there is no previous study which shade light on atypical presentation of Molluscum contagiosum.

References

1. Postlethwaite R. Molluscum contagiosum: A review. Arch Environ Health 1970;21:432-452. (2)
2. Billstein SA, Mattaliano VJ. The "nuisance" sexually transmitted disease: Molluscum contagiosum, scabies, crab lice. Med Clin North Am 1990; 74: 1487-1505. (3)
3. Becker TM, Blout JH, Douglas J, Judson FM. Trends in molluscum contagiosum in the United States, 1966-1983. Sex Transm Dis 1986; 13:88-92.(4)
4. Lombardo PC. Molluscum contagiosum and the acquired immunodeficiency syndrome. Arch Dermatol 1985; 121:834-835.(5)
5. Shwartz JJ, Mykowski PL: Molluscum contagiosum in patients with human immunodeficiency virus infection. J Am Acad Dermatol 1992; 27:583. (6)
6. Penneys NJ, Mutsuo S, Mogollon R. The identification of molluscum infection by immunohistochemical means. J Cutan Pathol 1986;13:97-101.(7)
7. Thompson CH. Identification and typing of molluscum contagiosum virus in clinical specimens by polymerase chain reaction. J Med Virol 1997;53:205- 211.(8)
8. Hanson D, Dayna GD. Dermatology Online J. 2007; 9(2): 2.(9)
9. Scholz J, Rosen-Wolff A, Burgert K et al. Epidemiology of molluscum contagiosum using genetic analysis of the viral DNA. J Med Virol 1989; 27: 87-90.
10. Porter CD, Archard LC: Characterization by restriction mapping of three subtypes of molluscum contagiosum virus. J Med Virol 1992; 38:1.
11. Gottlieb SL, Myskowki PL. Molluscum contagiosum. Int J Dermatol 1994;33:453-61.
12. Yamashita H, Uemura T, Kawashima M. Molecular epidemiologic analysis of Japanese patients with molluscum contagiosum. Int J Dermatol 1996; 35:99-105.
13. Nakamura J, Muraki Y, Yamada M, Hatano Y, Nii S. J Med Virol 1995;46(4):339-48.
14. Tom Wynniss & Friedlander Sheila Eds: Pox virus infection in: Fitzpatrick's dermatology general medicine ,seventh edition vol 4,1911-13. Eds: Wolff Klaus, Goldsmith Lowell, Katz Stephen, Gilchrist Barbara, Paller Amys & Leffee David.
15. Dohil MA . The epidemiology of molluscum contagiosum in children. J Am Acad Dermatol 2006;54:47.
16. Reynolds MG, Holman RC, Yorita Christensen KL, Cheek JE, Damon IK. The Incidence of Molluscum contagiosum among American Indians and Alaska Natives. PLoS One. 2009;4(4):e5255.
17. James, WD, Berger TG & Elston DM. Andrew's diseases of skin clinical dermatology eleventh edition 2011 sunders Elseiver , 389-9
18. Becker TM. Trends in molluscum contagiosum in the US, 1966-83. Sex Transm Dis 13:88, 1986
19. Brown J. Childhood molluscum contagiosum. Int J Dermatol. 2006;45,93-9.
20. Untoo RA, Shaheen N, Lone IA, Sheikh: Fulminant Ocular molluscum Contagiosum Indian Journal for the Practising Doctor . (2009-01-2009-02) Vol.5.No. 6 ,55.

*From the dept. of medicine
Al kindy college of medicine
E-mail myadr2000@yahoo.com