



Research Article

Automated breast ultrasound: A comparison study with handheld ultrasound in detection and characterization of lesions in mammographically dense breast

Saja Ali Ahmed^{1*}, Salam M. Joori²

¹ Department of Surgery, Al-Kindy College of Medicine, University of Baghdad, Baghdad, Iraq

² X-ray Institute, Medical City Complex, Ministry of health, Baghdad, Iraq

*Corresponding author: saja.a@kmc.uobaghdad.edu.iq

ABSTRACT

Article history:

Received 28 January 2022

Accepted 29 May 2022

Available online 31 August 2022

<https://doi.org/10.47723/kcmj.v18i2.794>

Keywords: automated breast ultrasound, handheld ultrasound, dense breast.



This article is an open access article distributed under the terms and conditions of the Creative Commons Attribution (CC BY) license

<http://creativecommons.org/licenses/by/4.0/>

Background: Although mammography is a powerful screening tool in detection of early breast cancer, it is imperfect, particularly for women with dense breast, which have a higher risk to develop cancer and decrease the sensitivity of mammogram, Automated breast ultrasound is a recently introduced ultrasonography technique, developed with the purpose to standardize breast ultrasonography and overcome some limitations of handheld ultrasound, this study aims to evaluate the diagnostic efficacy of Automated breast ultrasound and compare it with handheld ultrasound in the detection and characterization of breast lesions in women with dense breasts.

Objectives: To evaluate the diagnostic efficacy of Automated breast ultrasound and compare it with hand held ultrasound in detection and characterization of breast lesions in women with dense breast.

Subjects and Methods: A prospective observational study conducted at Oncology Teaching Hospital during the period of ten months from 1st of February till 1st of December 2020. Included 62 women with dense breasts on diagnostic mammograms. All women underwent technician performed automated breast ultrasound and radiologist performed handheld ultrasound for both breasts. All suspicious lesions with selected probably benign lesions underwent biopsy, handheld ultrasound detected 48 masses (67.6%), 15 of them (21.1%) were cystic, automated breast ultrasound detected 54 masses (76.1%); 20 of them (28.2%) were cystic. The sensitivity of handheld ultrasound was=87.5%, Specificity=58.8%, the sensitivity of automated breast ultrasound was=93.8%, Specificity=70.6%.

Conclusion: Automated breast ultrasound is an effective modality to detect occult breast lesion in women with dense breasts, automated breast ultrasound and handheld ultrasound have a reliable agreement in detection and characterization of breast lesions with higher accuracy of automated breast ultrasound in the evaluation of malignant lesions.

Introduction

The 3D (automated) breast ultrasound system is an invention that has been evolved to dissociate diagnosis from image acquiring and to undertake the limitations of handheld ultrasound. (1). Unlike HHUS, 3D-ABUS can be reproduced and barely depending on the

operator during image acquiring. Additionally, the image acquiring can be separated from image reporting, by this mechanism the image is obtained by a well-trained technician then reported by authorized radiologist at a separate place or at a separate date. (1). ABUS also produce a three-dimensional delineation for the entire breast, with

their formatted coronal image has been shown to enhance the accuracy of the diagnosis (2).

Limitations of 3D-ABUS include: more false-positive outcome and call-back, more shadows artifacts, cannot be used as a guidance in biopsy, axillary region cannot be evaluated, non-availability of elastography and colour doppler studies, more expensive machine compare to hand held US machine. (3,4,5)

Artefacts of ABUS: Nipple shadowing and reverberation artefacts: appear as an aligned echogenic band with parallel orientation, arranged side by side with same distant from each other (6).

Skip artefact: manifest transversally as non-echoic band, it can be used as an indicator of underlying pathology. (7). **Motion artefact:** present as numerous wavy echogenic lines. (8). **Contact artefact:** occur due to in proper contact in between probe and chest wall produce hypoechoic non regular region (8). A specific descriptor for malignancies at ABUS is the retraction phenomenon, Result shown that retraction is usually evident in relatively slow growing malignancy with a poor proliferation rate (9).

Aim of study: To evaluate the diagnostic efficacy of Automated breast ultrasound and compare it with hand held ultrasound in detection and characterization of breast lesions in women with dense breast.

Subjects and Methods

Study design and data collection time A prospective observational study was conducted at Oncology Teaching Hospital in Baghdad Medical City during the period of ten months from 1st of February till 1st of December 2020

Study patients and sample size 62 women were diagnosed with dense breasts (ACR type C–D) on diagnostic mammograms and underwent bilateral whole breast ultrasound. Technician performed ABUS and radiologist performed HHUS for both breasts. All suspicious (breast imaging reporting and data system-BIRADS IV–V) and randomly selected lesions with BIRAD III findings detected on either modality had undergone U/S guided core needle biopsy with a 16 - 18G needle.

Inclusion criteria

women with dense breasts (ACR type C–D) on diagnostic mammograms.

Exclusion criteria

1. Women with category A and B breast density on mammography.
2. women who refuses ABUS examination and women.
3. women with recent breast intervention.

Equipment and techniques Hand-held ultrasound were performed by GE LOGIC S8 machine using a 4–15 MHz linear transducer (ML6-15). The expert radiologist (14 years' experience) performed it with woman lies in supine position after exposure of the region with ipsilateral arm bring up and the hand on the head, the entire time for the examination was approximately 20 min for both breasts, ABUS was performed by Acuson S2000 automated breast volumetric scan, Siemens Healthcare, carried out by a trained technician (2 months training), the transducer wide-frequency bandwidth (5-14 MHz) catch about 6 cm × 15.4 cm × 16.8 cm volume with a series of 320 high-resolution axial 2D images of 0.5

mm slice intervals, customized options were used to optimize frequency, depth and gain. The study had performed with the patient lying supine, a pillow is placed under the patient on the same side to be imaged; to maximize proximity between transducer and chest wall. With exposed breast of the breast, abundant quantity of lotion is applied on the breast with additional quantity on the region around the areolar and nipple to ensure optimal study with mild compression was applied by a transducer to avoid artefacts. With the nipple as a central mark, the anterior posterior (AP) orientation initially captured. Lateral orientation usually captured with the transducer angled from axillary region toward the sternal region and for the medial orientation with the transducer angled from the sternal region to the axillary region, the time for the acquisition of the image was approximately 15 min for both breasts,

Image analysis and interpretations both HHUS and ABUS are interpreted by expert radiologists in breast imaging. Interpretation done for: lesion detection, Characterization of lesion : Shape (Oval, round, or irregular), Orientation (parallel, not parallel), Margin (circumscribed, micro lobulated, angular, indistinct, spiculated), Echogenicity characteristic (non-echoic, hypo-echoic, iso-echoic, hyperechoic, heterogeneous, complex cyst and solid), Posterior characteristic (no features, shadowing, enhancing, combined pattern), Lesion location (clock-face and distance from the nipple in millimetres), and largest diameter (in millimetres), a BI-RADS finally reported for each lesion as one of these categories : Negative, Benign, probably benign (2% risk of malignancy), suspicion (3–94% risk of malignancy), Highly suspicious of malignancy (95% or greater likelihood of malignancy). Breast lesions with BIRAD IV & V with randomly selected BIRAD III lesions, underwent histopathological diagnosis at the pathology department of the hospital following core biopsy using a 16-18 gauge needle or surgical excisional biopsy.

Ethical considerations and official approvals Verbal permission was taken from each woman preceding data collection, and the details was kept anonymous, administrative approvals were conceded from: The Council of Iraqi Board of Medical Specialization, Oncology Teaching Hospital in Baghdad Medical City.

Statistical analysis the data reanalysed Statistical Package of Social Sciences (SPSS) version 25, Cohen's Kappa Coefficient (K) measured inter-rater agreement for qualitative (categorical) items. A degree of P-value below 0.05 was regarded significance.

Results

The numbers of women included in the study was totally 62, age was ranging from 39 – 60 years (mean of 46.72 years) with 71 breast cases (nine patients with bilateral abnormality). They were evaluated by HHUS and ABUS, HHUS detected a mass in 48 cases (67.6%); 15 of them (21.1%) were cystic lesions; While ABUS detected a mass in 54 lesions in comparison, all lesions detected in HHUS were detected by ABUS with addition of 6 lesion (76.1%); 20 of them (28.2%) were cystic lesions.

Table 1: Comparison in mass detection between HHUS and ABUS.

Mass detection by HHUS	Mass detection by ABUS		Total	Kappa value	P-value
	Yes	No			
Yes	48	0	48	0.793	0.001
No	6	17	23		
Total	54	17	71		

Table 2: Comparison in mass shape between HHUS and ABUS

Mass shape by HHUS	Mass shape by ABUS			Total	Kappa value	P-value
	Oval	Round	Irregular			
Oval	11	0	1	12	0.936	0.001
Round	0	2	0	2		
Irregular	0	0	14	14		
Total	11	2	15	28		

By ABUS, the margin was circumscribed in 12 of them; all of them were confirmed by HHUS.

In conclusion, there was a substantial agreement between the margin by HHUS and ABUS, and this agreement was statistically significant (kappa= 0.634, P=0.001).

By ABUS, the echo pattern was hypoechoic in 23 lesions; 21 of them were confirmed by HHUS.

In conclusion, there was a moderate agreement between the echo pattern by HHUS and ABUS, and this agreement was statistically significant (kappa= 0.62, P=0.001).

By ABUS, the posterior feature was not detected in 16 lesions; all of them were confirmed by HHUS; there was a perfect agreement between the posterior feature by HHUS and ABUS, and this agreement was statistically significant (kappa= 0.85, P=0.001).

Table 3: Comparison in BIRAD between HHUS and ABUS.

BIRAD by HHUS	BIRAD by ABUS					Total	Kappa value	P-value
	I	II	III	IV	V			
I	7	4	2	0	0	13	0.719	0.001
II	0	13	0	0	0	13		
III	0	5	15	1	0	17		
IV	0	3	0	20	0	23		
V	0	0	0	0	1	1		
Total	7	25	17	21	1	71		

In this study, 33 lesions underwent histopathological examination; 16 of them were malignant (48.5%); table 4 shows the sensitivity, specificity, and accuracy of HHUS in diagnosing malignant lesions. The sensitivity of HHUS was = 87.5%, specificity = 58.8% and accuracy was 72.7%. +ve predictive value was 66.7%, while -ve predictive value was 83.3%.

Table 4: Sensitivity, specificity, and accuracy of HHUS in the diagnosis of malignant lesion

BIRAD by HHUS	Histopathological Finding		Total
	Malignant	Benign	
Suspicious (IV, V)	14	7	21
Probably Benign (III)	2	10	12
Total	16	17	33

Table 5 shows the sensitivity, specificity, and accuracy of ABUS in diagnosing malignant lesions.

The sensitivity of ABUS was = 93.8%, specificity = 70.6% and accuracy was 81.8%.

+ve predictive value was 75%, while -ve predictive value was 92.3%.

Table 5: Sensitivity, specificity, and accuracy of ABUS in the diagnosis of malignant lesion

BIRAD by ABUS	Histopathological Finding		Total
	Malignant	Benign	
Suspicious (IV, V)	15	5	20
Probably Benign (III)	1	12	13
Total	16	17	33

By ABUS, 48 patients were detected positive; 30 of them confirmed by mammogram. In conclusion, there was no statistically significant agreement (P= 0.07) between patient detection by mammogram and ABUS. We noticed that from 35 detected lesions by mammogram, 20 were asymmetrical, and 15 were masses; from these 20 asymmetrical, 15 were positive, as shown in table(6).

Table 6: Comparison in lesions detection between mammogram and ABUS.

Patients by mammogram	Patients by ABUS		Total	Kappa value	P - value
	Positive	Negative			
Positive	30	5	35	0.202	0.07
Negative	18	9	27		
Total	48	14	62		

(HHUS: hand held ultra sound, ABUS: automated breast ultrasound, BIRAD: breast imaging reporting and data system)

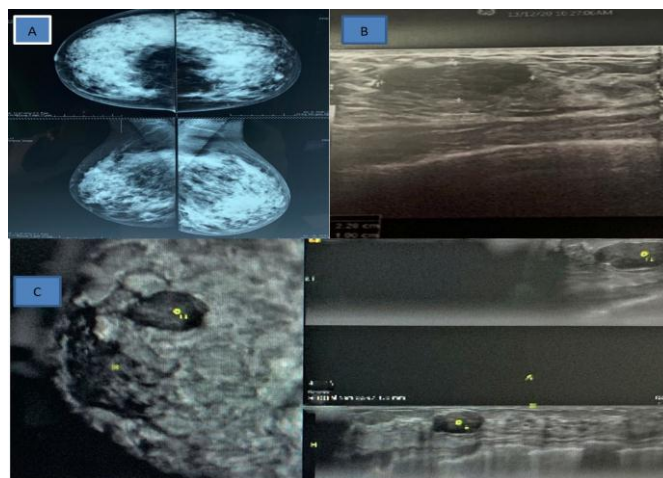


Figure1: Female patient 39 years old with histopathological diagnosis of fibroadenoma. A. Mammogram (cranio-caudal and Medio lateral oblique views of both breasts) showing dense breast (ACR D) with left sided equal density and obscured margin mass seen. B. HHUS image showing a parallel hypoechoic lesion in the upper outer quadrant of the left breast measuring 22*10mm. C. coronal, axial and sagittal reformatted ABUS image showing the well-defined hypoechoic lesion 25*11 mm which had a fine lobulated outline. The lesion was graded BI-RADS III.

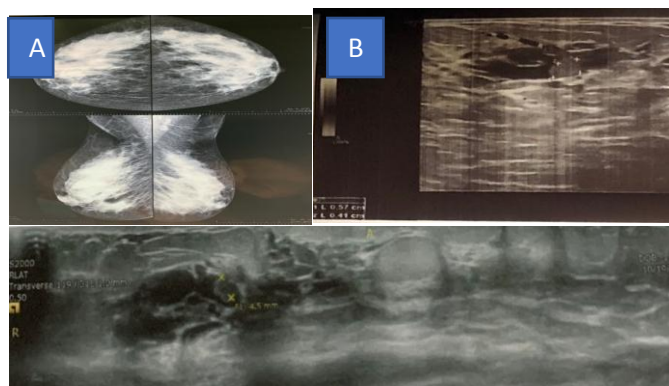


Figure 2: Female patient 42 years old with histopathological diagnosis of intra-cystic papilloma. A Mammogram (cranio-caudal and mediolateral oblique views of both breasts) showing dense breast (ACR D) with no obvious lesions or calcifications B. HHUS image show complex cystic lesion with 5.7 mm solid component. Axial reformatted ABUS image showing the complex cystic lesion with small solid component the lesion was graded BI-RADS IV on both imaging modality.

Discussion

Female with high fibro-glandular breast tissue dense breasts have a high risk for developing breast malignancy, and furtherly encountered less detection rate of breast pathology on mammogram due to obscuring effect of the hyper-dense parenchyma. As a result, other techniques needed for imaging

Like ultrasound, tomosyntheses or magnetic resonance imaging to enhance the evaluation for the female with high dense breast (10). ABUS can provide a three-dimensional delineation of the entire breasts, with the coronal orientation significantly increase the accuracy of the diagnosis. Automated breast ultrasound has superior than or similar achievement to hand held ultrasound(11).Regarding mass detection in this study, and by ABUS, mass was detected in 54 lesions; 48 of them were confirmed by HHUS, there was a substantial agreement between the mass detection of HHUS and ABUS, and this agreement was significant ($\kappa=0.793$, $P=0.001$). Kim and colleagues reported a different result in their study that was conducted in 2014, they found a moderate agreement on detection of mass observed by HHUS and ABUS in the assessment of breast lesion ($\kappa=0.472$) (12). This discrepancy can be explained by differences in sample size, operated dependency of HHU and ABUS reader has little experience with ABUS imaging (13). Concerning the mass shape in the current study and by ABUS, mass was irregular in 15 of them; 14 of them were confirmed by HHUS. As a result, there was a perfect agreement between the mass shape of HHUS and ABUS, and this agreement was statistically significant ($\kappa=0.936$, $P=0.001$). Different results were observed in Kim et al study in 2014, as observed a substantial agreement on the description of shape by HHUS and ABUS ($\kappa=0.707$) (12). In the same manner, Shin and colleagues in the study conducted in 2011, found a Substantial agreement between HHUS and ABUS for assessment of shape ($\kappa=0.71$). The agreement was more for irregular ($K=0.76$) shape and lower for rounded ($\kappa = 0.25$) shape (14). assessment of margin by ABUS in the present study showed that it was circumscribed in 12 of them; all of them were confirmed by HHUS. In conclusion, there was a substantial agreement between the margin by HHUS and ABUS, and this agreement was statistically significant ($\text{Kappa}=0.634$, $P=0.001$). An agreement to the present work was noticed in Shin et al study in 2011, they observed a

substantial agreement between HHUS and ABUS founded to assess the margin ($\kappa = 0.61$). there was about perfect agreement when classified margins into two groups: circumscribe margin or not circumscribed ($\kappa = 0.808$) (14). Kim and colleagues reported a different result in their study that conducted in 2014, they found a moderate agreement on margin detection by HHUS and ABUS ($\kappa=0.438$) (12), this can be explained by depended on proper orientation, angulation and compression of the probe which can affect the proper interpretation of the shape, also with proper machine setting (15)On the other hand, the Echo pattern assessment by ABUS in the present work was hypoechoic in 23 lesions; 21 of them were confirmed by HHUS. In conclusion, there was a moderate agreement between the echo pattern by HHUS and ABUS, and this agreement was statistically significant ($\text{Kappa}=0.62$, $P=0.001$). In the same manner, Kim and colleagues found a similar result in a study conducted in 2014, they found a moderate agreement on echogenicity detected by HHUS and ABUS ($\kappa=0.524$) (12), which also agreed to the study conducted in 2011, by Shin and colleagues. They found in the comparison between HHUS and ABUS that a moderate agreement was founded in the assessment of echogenicity in-between radiologist ($K=0.45$) (14)The posterior feature assessed by ABUS in this study revealed that it was not detected in 16 lesions; all of them were confirmed by HHUS. In conclusion, there was a perfect agreement between the posterior feature by HHUS and ABUS, and this agreement was statistically significant ($\text{Kappa}=0.85$, $P=0.001$). Kim and colleagues found a different result in a study conducted in 2014, they found a moderate agreement on posterior acoustic features detected by HHUS and ABUS ($K=0.541$) (12)which was by Shin et al study in 2011, as a moderate agreement was accomplished in the interpretation of posterior acoustic characteristics by HHUS and ABUS ($K=0.42$) (14),this may be affected by different in manipulation and gain of the machine setting which can significantly affect the posterior feature of the lesion. Finally, by ABUS in the current study, BIRAD was II in 25 lesions; 13 of them were confirmed by HHUS. In conclusion, there was a substantial agreement between the BIRAD by HHUS and ABUS, this agreement was statistically significant ($\kappa=0.688$, $P=0.001$). The current results agreed to that observed in Shin et al study in 2011, as noticed in terms of an agreement on BI-RADS features of breast masses comparison of the HHUS and ABUS, substantial agreement founded in the assessment finally ($K=0.64$) (14).Different results were observed when compared to Kim et al study in 2014, as reported that BI-RADS final assessment yielded fair agreement ($K=0.397$) (12). Differently, a recent prospective study done by Vourtsis and others in 2018, involving 1,886 patients reported the excellent overall agreement (99.8%) between HHUS and ABUS, with a kappa value of 0.994. They concluded that ABUS could be successfully used in the visualization and characterization of breast lesions. Also, ABUS seemed to outperform HHUS in the detection of architectural distortion on the coronal plane and can supplement mammography in the detection of non-calcified carcinomas in those who had dense breasts (15) In the current study, the sensitivity of HHUS was=87.5%, specificity = 58.8% and accuracy was 72.7%, positive predictive value was 66.7%, while -ve predictive value was 83.3%. On the other hand, the sensitivity of ABUS was=93.8%, specificity=70.6% and accuracy were 81.8%. The positive predictive value was 75%, while the -ve predictive value was 92.3%. by compare with another studies, close outcome seen in Jia et al study in 2020, as noticed that female with high breast density on

mammogram, when 3D ultrasound was utilized as an adjacent study, the sensitivity reached about 99.10% and the specificity reached to 86.87%. The positive predictive value and negative predictive value were 69.97%, 99.68% respectively (16). Better results were observed in Lin et al study in 2012, in which both ABUS and HHUS detected 95 breast lesions. Compared with the pathological diagnosis in 35 lesions, both ABUS and HHUS exhibited high sensitivity (both 100%) and high specificity (95.0%, and 85.0%, respectively). On the other hand, Golatt and colleagues in a study done in 2015, concluded that ABUS might be a helpful new tool in breast imaging, especially in screening, as found a high NPV of 98%, a high specificity of 85% and a sensitivity of 74% based on the cases with US-guided biopsy. Including the cases where the lesion was seen in a second-look ABUS the sensitivity improved to 84% (NPV=99%, Specificity=85%) (87). Finally, ABUS was comparable to HHUS in Schmachtenberg et al study in 2017, in terms of sensitivity (93.3% vs. 100%), specificity (83.3% vs. 83.3%), accuracy (87.2% vs. 89.7%), positive predictive value (77.8% vs. 78.9%), and negative predictive value (95.2% vs. 100%) (17). The differences observed in the above studies can be explained by a different sample size of each study, the experience of the operator in performance of examination and radiologist in interpretation, and false-positive results with benign pathologies as focal fibrosis, fibroadenomas, inframammary lipoma, and fibrocystic changes, with and without inflammatory change. By ABUS in this study, 48 patients were detected positive (mass); 35 of them confirmed by mammogram (mass or asymmetry). In conclusion, there was no statistical significant agreement ($P=0.07$) between patient detection by mammogram and ABUS. In comparison to other studies, a similar finding was observed in a study done by Abd Elkhalek and colleagues in 2019 that shows in all the results of the mammogram study, ABUS can detect it without significant change ($P>0.05$). They concluded that ABUS has advantages of better diagnostic accuracy of breast lesions in terms of early detection, better categorization, and accurate assessment. ABUS with mammography will add more value in the diagnostic field (18).

limitations of this study include:

- As it is a newly introducing modality, ABUS imaging still not very familiar to the technicians and radiologists.
- The technique itself is limited, as are other sonography techniques, in women with large or pendulous breasts.
- Patient cooperation is also necessary as motion beyond quiet breathing will degrade the examination.
- small sample size which mostly affected by the COVID 19 pandemic.

Funding

This research did not receive any specific fund.

Conflict of Interest

No conflict of interest

Conclusions

TcB In conclusion, ABUS is an effective modality to detect occult breast lesions in female with high density breast parenchyma on mammogram, automated breast(3D) ultrasound and handheld(2D) ultrasound have a reliable agreement in detection and characterization of breast lesions in women with dense breasts, with

higher accuracy of ABUS in the evaluation of malignant lesions. High percentage of women with dense breast and the several benefits of automated breast ultrasound above handheld ultrasound, like reproducibility, operator-independent, less time-consuming, ABUS manifest considerable capability to be applied in breast Imaging.

References

- [1] Vourtsis AJD, imaging i. Three-dimensional automated breast ultrasound: technical aspects and first results. 2019;100(10):579-92.
- [2] Rella R, Belli P, Giuliani M, Bufi E, Carlino G, Rinaldi P, et al. Automated breast ultrasonography (ABUS) in the screening and diagnostic setting: indications and practical use. 2018;25(11):1457-70.
- [3] Mundinger AJTJoBH. 3D supine automated ultrasound (saus, abus, abvs) for supplemental screening women with dense breasts. 2016;12(2):52.
- [4] Shin HJ, Kim HH, Cha JHJU. Current status of automated breast ultrasonography. 2015;34(3):165.
- [5] Scheel JR, Lee JM, Sprague BL, Lee CI, Lehman CDJAjoo, gynecology. Screening ultrasound as an adjunct to mammography in women with mammographically dense breasts. 2015;212(1):9-17.
- [6] Baad M, Lu ZF, Reiser I, Paushter DJR. Clinical significance of US artifacts. 2017;37(5):1408-23.
- [7] Dubelaar I, Fassaert T, de Jong M, Rutten M, editors. Automated breast volume scanning: technique and artefacts 2011: European Congress of Radiology-ECR 2011.
- [8] Kim SHJU. Image quality and artifacts in automated breast ultrasonography. 2019;38(1):83.
- [9] van Zelst JC, Mann RMJR. Automated three-dimensional breast US for screening: technique, artifacts, and lesion characterization. 2018;38(3):663-83.
- [10] Liu J, Liu P-F, Li J-N, Qing C, Ji Y, Hao X-S, et al. Analysis of mammographic breast density in a group of screening Chinese women and breast cancer patients. 2014;15(15):6411-4.
- [11] Hellgren R, Dickman P, Leifland K, Saracco A, Hall P, Celebioglu FJAR. Comparison of handheld ultrasound and automated breast ultrasound in women recalled after mammography screening. 2017;58(5):515-20.
- [12] Kim EJ, Kim SH, Kang BJ, Kim YJJU. Interobserver agreement on the interpretation of automated whole breast ultrasonography. 2014;33(4):252.
- [13] Tutar B, Esen Icten G, Guldogan N, Kara H, Arıkan AE, Tutar O, et al. Comparison of automated versus hand-held breast US in supplemental screening in asymptomatic women with dense breasts: is there a difference regarding woman preference, lesion detection and lesion characterization? 2020;301(5):1257-65.
- [14] Shin HJ, Kim HH, Cha JH, Park JH, Lee KE, Kim JHJA-AJoR. Automated ultrasound of the breast for diagnosis: interobserver agreement on lesion detection and characterization. 2011;197(3):747.

- [15] Vourtsis A, Kachulis AJEr. The performance of 3D ABUS versus HHUS in the visualisation and BI-RADS characterisation of breast lesions in a large cohort of 1,886 women. 2018;28(2):592-601.
- [16] Jia M, Lin X, Zhou X, Yan H, Chen Y, Liu P, et al. Diagnostic performance of automated breast ultrasound and handheld ultrasound in women with dense breasts. 2020;181(3):589-97.
- [17] Golatta M, Baggs C, Schweitzer-Martin M, Domschke C, Schott S, Harcos A, et al. Evaluation of an automated breast 3D-ultrasound system by comparing it with hand-held ultrasound (HHUS) and mammography. 2015;291(4):889-95.
- [18] Abd Elkhalek YI, Bassiouny AM, Hamid RWARAJEJoR, Medicine N. Automated breast ultrasound system (ABUS): can it replace mammography as a screening tool? 2019;50(1):1-8.

To cite this article: Ahmed S, Joori S. Automated breast ultrasound: A comparison study with handheld ultrasound in detection and characterization of lesions in mammographically dense breast. *Al-Kindy College Medical Journal*. 2022;18(2):112-117.