



Case Report

Absence of the Musculocutaneous Nerve; Two Case Reports and Literature Review

Mohammed A. Abdelmotalab

Anatomy Department, Faculty of Medicine, International University of Africa, Sudan

* Corresponding author's email: salam_ahamed@yahoo.com

ABSTRACT

Article history:

Received 29 July 2022

Accepted 28 September 2022

Available online 1 April 2024

<https://doi.org/10.47723/2zj9sm98>

Keywords: Musculocutaneous nerve, Median nerve, Bilateral, Variations



This article is an open access article distributed under the terms and conditions of the Creative Commons Attribution (CC BY) license

<http://creativecommons.org/licenses/by/4.0/>

The musculocutaneous nerve is important in the upper extremity because it provides motor innervation to the musculature of the anterior arm region and sensory innervation to the skin on the lateral side of the forearm region. During the dissection of approximately 74 aged male cadaver for the 2021-2022 academic year at the Department of Anatomy, Faculty of Medicine, International University of Africa, Sudan. Considerable variation was present; the musculocutaneous nerve was observed to be absent in both upper extremities. The median nerve replaces the musculocutaneous nerve innervation's role on both sides except for the coracobrachialis muscle on the right side. A direct branch from the lateral cord innervated it. Reporting these variations has a critical impact on many surgical and clinical procedures.

Introduction

The brachial plexus arises from C5, 6, 7, 8 and T1 anterior rami, it has four levels: root, trunks, divisions, and cords. The three cords and their branches were lactated at the armpit (1). The musculocutaneous nerve is the terminal branch of the lateral cord of the brachial plexus, it originates from the C 5, 6 and 7 roots. After exiting the axilla, it perforates the coracobrachialis muscle and continues between the biceps brachii and brachialis muscles, supplying them with motor innervations and emerging as lateral cutaneous nerve of the forearm (2). The prevalence of limb musculocutaneous nerve absence ranged from 1.66% to 13.33% (3). The absence of the musculocutaneous nerve was found in 8% of the 24 dissected cases (4).

This case expresses the absence of the musculocutaneous nerve and the role of the median nerve to replace its function with respect to variants in branches and distributions in the upper extremities. Fig. 1, 2 and 3.

Case report presentation:

During routine dissection of a 74-year-old formalin-fixed male cadaver for the 2021-2022 academic year at the Department of Anatomy, Faculty of Medicine, International University of Africa, Sudan. After complete dissection and cleaning of the upper structures of the upper extremities according to the guidance of Cunningham's Manual of Practical Anatomy. Bilateral absence of the

musculocutaneous nerve was observed in two upper extremities. The variation was first observed on the left side, so the right side was dissected for comparable variation.

Case 1; Left side variations:

The musculocutaneous nerve was absent in the left upper extremity, all muscles of the anterior aspect of the arm were innervated by the median nerve. The median nerve was formed by medial and lateral roots in front of the brachial artery, following the course of the median nerve, about 1 cm long, a branch arises from the lateral side of the nerve trunk for innervation of the coracobrachialis, biceps brachii and brachialis muscles. The branch to the biceps brachii continues downward to innervate the biceps muscle and exits near the biceps tendon in the roof of the elbow to continue as a sensory nerve for the lateral aspect of the forearm, as shown in (Fig.1).




Figure. 1: shows the left area of the armpit and arm; The median nerve (MN) gave off a branch that innervated the coracobrachialis muscle (CBM), the biceps muscle (BBM), and the brachialis muscle (BM). The lateral cutaneous nerve of the forearm (LCNF) is the continuation of the branch to the biceps brachii muscle.

Case 2; Right side variations:

The musculocutaneous nerve was absent in the right upper extremity. When the structures were fully exposed, a narrow nerve approximately 5 cm long, originating from the lateral cord of the brachial plexus, descended to innervate the coracobrachialis muscle (Fig. 3). The median nerve was formed on the right side by the union of medial and lateral roots at the anterior aspect of the brachial artery. When the median nerve traverses approximately 2.65 cm, a first branch arises in the upper part of the arm to innervate the biceps brachii. However, after the median nerve had passed approximately 1.42 cm, another second branch rose from the median nerve just distal to the first approximately 1.30 cm. The second branch runs between the biceps and brachialis muscles to innervate the brachialis muscle and then exits in the cubital fossa near the biceps tendon and continues as the lateral cutaneous nerve of the forearm as shown in (Fig.2).

Discussion

The variation of the musculoskeletal nerve has been described in many studies presenting its communication and absence. The musculocutaneous nerve was absent on both sides and the arm muscles were innervated by the median nerve. The left coracobrachialis muscle was directly innervated by the lateral cord of

the brachial plexus (5). A 65-year-old male with brachial plexus characterized by the absence of the musculocutaneous nerve. The median nerve replaces the motor and sensory areas that supply the musculocutaneous nerve. The coracobrachialis muscle was bilaterally innervated by a branch of the lateral cord. Two branches arise from the median nerve for the biceps brachii and the brachialis. The nerve to the brachialis muscle continued as the lateral cutaneous nerve of the forearm (6).

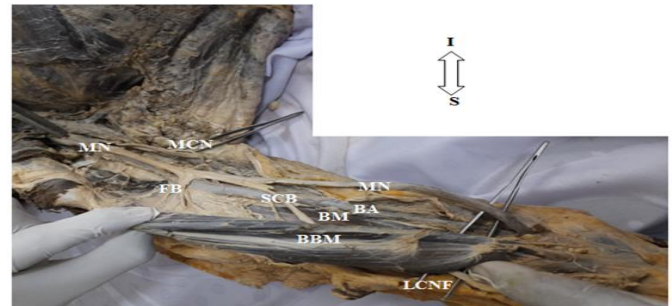


Figure. 2: showing the area of axilla and arm; Median nerve(MN), First branch of median nerve(FB), second branch of median nerve(SCB), medial cutaneous nerve of the forearm(MCN),brachial artery(BA), coracobrachialis muscle(CBM), biceps brachii muscle (BBM), brachii muscle (BM) and lateral cutaneous nerve of the forearm (LCNF).

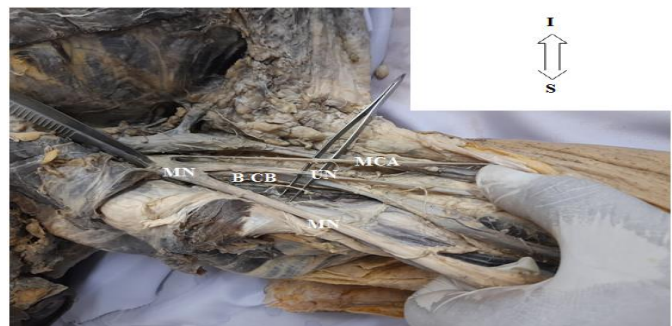

Figure. 3: showing the branches of brachial plexus in the right axillary region. And absence of musculocutaneous nerve, the direct branch from the lateral cord innervates the CB (BCB).

Ishwar B. et al, describes a 58-year-old Indian cadaver observed to be missing a musculocutaneous nerve in both upper limbs and the arm muscles were innervated by the lateral root of the median nerve (7). Sakkarai Jayagandhi et al. mentioned the bilateral absence of the musculocutaneous nerve in two cases in male cadavers aged 60 and 65 years, and the muscles of the anterior arm compartment were innervated by the branches of the median nerve (8). In the present cases, the musculocutaneous nerve was absent on both sides, as for the left side, near the beginning of the median nerve, a branch rose from the median nerve, provide the coracobrachialis, biceps brachii, and brachialis muscles, each with a separate branch supplied. However, on the right side, the coracobrachialis muscle was innervated by a branch from the lateral trunk of the brachial plexus, while the biceps and brachialis were innervated by separate branches directly from the median nerve trunk.

In type V Le Minor classification, the musculocutaneous nerve is absent, and the muscles of the forearm are supplied by the median

nerve. The current cases are consistent with this classification (9). In a study with sixty subjects, the bilateral absence of the musculocutaneous nerve was determined. The anterior flexor muscles of the arm were supplied by the median nerve, and the coracobrachialis muscle was innervated by the lateral cord of the brachial plexus. A branch of the median nerve was continued as a lateral cutaneous nerve of the forearm. According to this study, this was comparable to the right upper extremity case (10).

M.E. Aydin et al. found musculocutaneous nerve failure in a 58-year-old male cadaver. They mention that the nerve supply to the biceps brachii and brachialis muscles came from two separate branches of the median nerve, one branch arose from the nerve trunk almost mid-arm, it was again divided into a motor branch to the brachialis muscle and a sensory branch giving sense of the lateral part of the forearm (11). A 43-year-old female cadaver presented with a complete bilateral absence of the musculocutaneous nerves. The anterior compartment muscles of both arms were supplied by the median nerve, with the exception of the coracobrachialis, which was innervated by a direct branch from the lateral cord of the brachial plexus. The median nerve, after supplying the biceps and brachialis muscles, gave off to the lateral cutaneous nerve of the forearm (12). The nerve to the brachialis muscle continued as the lateral cutaneous nerve of the forearm (6). According to the findings of the present cases, the coracobrachialis on the left side was innervated by the median nerve. The lateral cutaneous nerve of the forearm on the left is the continuation of the branch of the biceps brachii, meaning that this branch carries motor and sensory components. On the other hand, the lateral cutaneous nerve on the forearm was a continuation of the branch to the brachialis muscle, which originated directly from the median nerve.

Conclusion

The musculocutaneous nerve was absent in both upper extremities. The median nerve supplies the anterior compartment of the arm except for the right coracobrachialis muscle. Reporting these abnormalities has a critical impact on many surgical and clinical procedures. The student should be involved in discussions about anatomical variations to increase their level of performance.

Acknowledgements

The author would like to thank the students of Batch 21 at the International University of Africa Faculty of Medicine for their help during the dissection phase and for jointly discussing and responding to the two cases during the laboratory session..

Funding

This research did not receive any specific fund.

Conflict of Interest

Authors declare no conflict of interest.

ORCID

Mohammed Abdelmotalab [0000-0003-3110-311X](https://orcid.org/0000-0003-3110-311X)

References

- [1] McMinn RMH. (1994). Last's Anatomy. 9th ELBSEd. Churchill Livingstone, Singapore: pp 65-156.
- [2] Harold Ellis. Clinical Anatomy, Applied anatomy for students and junior doctors. 2006; 11th Ed, Blackwell Publishing Ltd: pp 159-203.
- [3] Hunter DD, Zdilla MJ. The absent musculocutaneous nerve: A systematic review. Translational Research in Anatomy. 2021 Jan 1;22:100092. <http://dx.doi.org/10.1016/j.tria.2020.100092>
- [4] Prasada Rao PV, Chaudhary SC. Absence of musculocutaneous nerve: two case reports. Clinical Anatomy. 2001 Jan;14(1):31-5. [https://doi.org/10.1002/1098-2353\(200101\)14:1%3C31::aid-ca1005%3E3.0.co;2-y](https://doi.org/10.1002/1098-2353(200101)14:1%3C31::aid-ca1005%3E3.0.co;2-y)
- [5] Sakar A, Saha A. Bilateral absence of musculocutaneous nerve: A case report. Journal of Clinical and Diagnostic Research: JCDR. 2014 Sep;8(9):AD06. <https://doi.org/10.7860/2FJCDR%2F2014%2F8779.4903>
- [6] Candan B, Öztürk K, Albay S. Bilateral absence of musculocutaneous nerve with unusual communicating branch between radial and ulnar nerves. International Journal of Anatomical Variations. 2016;9. <https://doi.org/10.5115%2Fajb.2012.45.3.207>
- [7] Bagoji IB, Balappa MD, Patil MB. Bilateral absence of musculocutaneous nerve and its clinical and surgical implications.
- [8] Sakkarai Jayagandhi , Rajalakshmi Rajasegaran ,Suman Verma , Virender Kumar Nim. Bilateral Absence of Musculocutaneous Nerve: Report of Two Cases. Int J Anat Res.2018; 6(2.1):5110-13. <https://doi.org/10.7860/2FJCDR%2F2014%2F8779.4903>
- [9] Le Minor JM. A rare variation of the median and musculocutaneous nerves in man. Archives d'anatomie, d'histologie et d'embryologie normales et experimentales. 1990 Jan 1;73:33-42.
- [10] Priya A, Gupta C, D'souza AS. Cadaveric study of anatomical variations in the musculocutaneous nerve and in the median nerve. Journal of Morphological Sciences. 2019 Jun;36(02):122-5. <https://doi.org/10.1055/s-0039-1688799>
- [11] Aydin ME, Kale A, Edizer M, Kopuz C, Demir MT, Corumlu U. Absence of the musculocutaneous nerve together with unusual innervation of the median nerve. Folia Morphologica. 2006;65(3):228-31.
- [12] Bhanu PS, Sankar KD. Bilateral absence of musculocutaneous nerve with unusual branching pattern of lateral cord and median nerve of brachial plexus. Anatomy & Cell Biology. 2012 Sep 1;45(3):207-10. <https://doi.org/10.5115%2Fajb.2012.45.3.207>

To cite this article: Abdelmotalab, MA. Absence of the musculocutaneous nerve; Two case reports and literature review. AL-Kindy College Medical Journal, 2024;20(1), 71-73. <https://doi.org/10.47723/2zj9sm98>